



MASSACHUSETTS
GENERAL HOSPITAL

PSYCHIATRY ACADEMY

Skin Souvenirs: Rashes in Returning Travelers

Esther Freeman MD PhD

Director, Global Health Dermatology

Massachusetts General Hospital

Associate Professor, Harvard Medical School

Disclosures

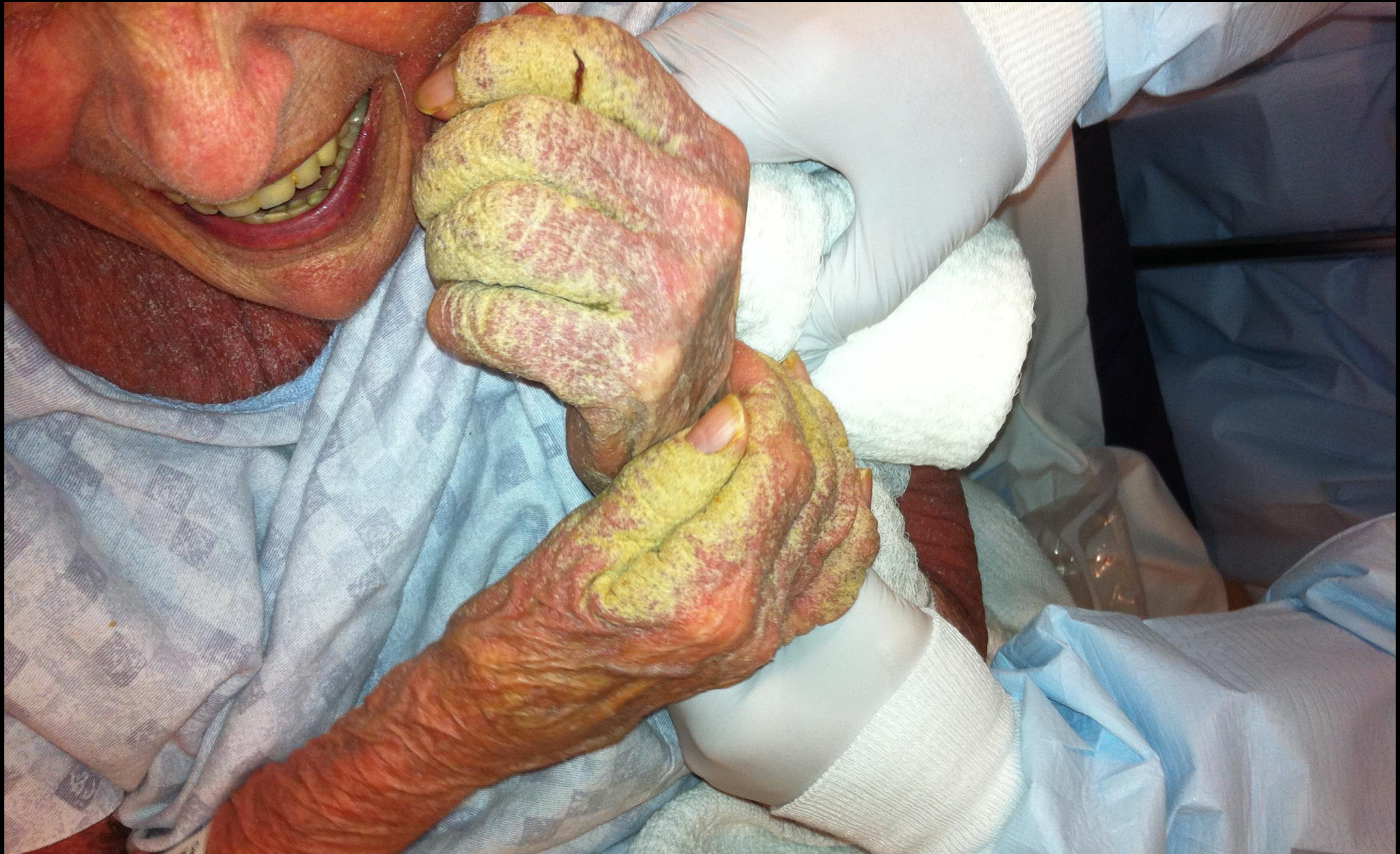NIH K23 funding for HIV Dermatology

UpToDate author: COVID-19 Dermatology

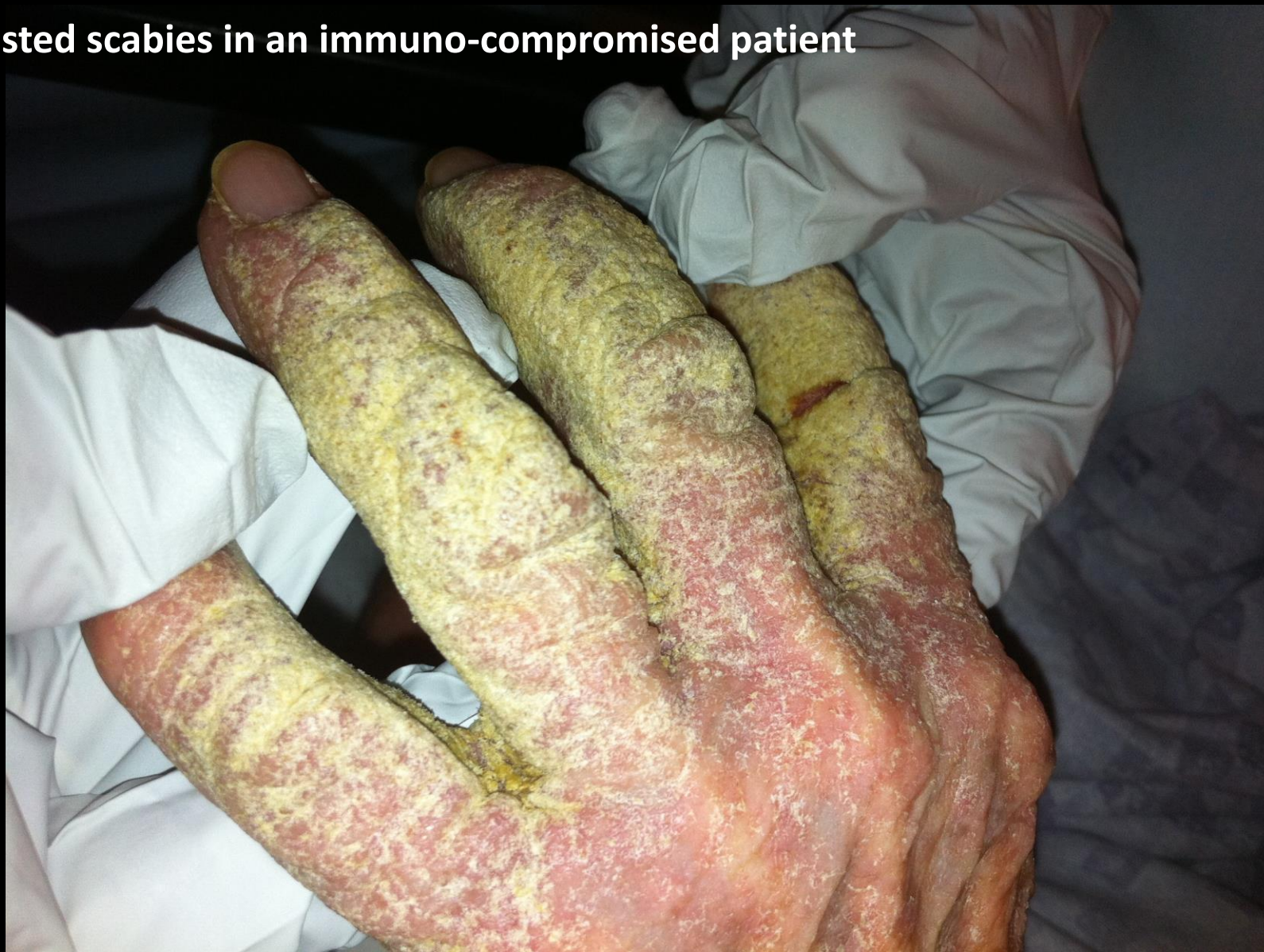ILDS Grant for COVID-19 Dermatology

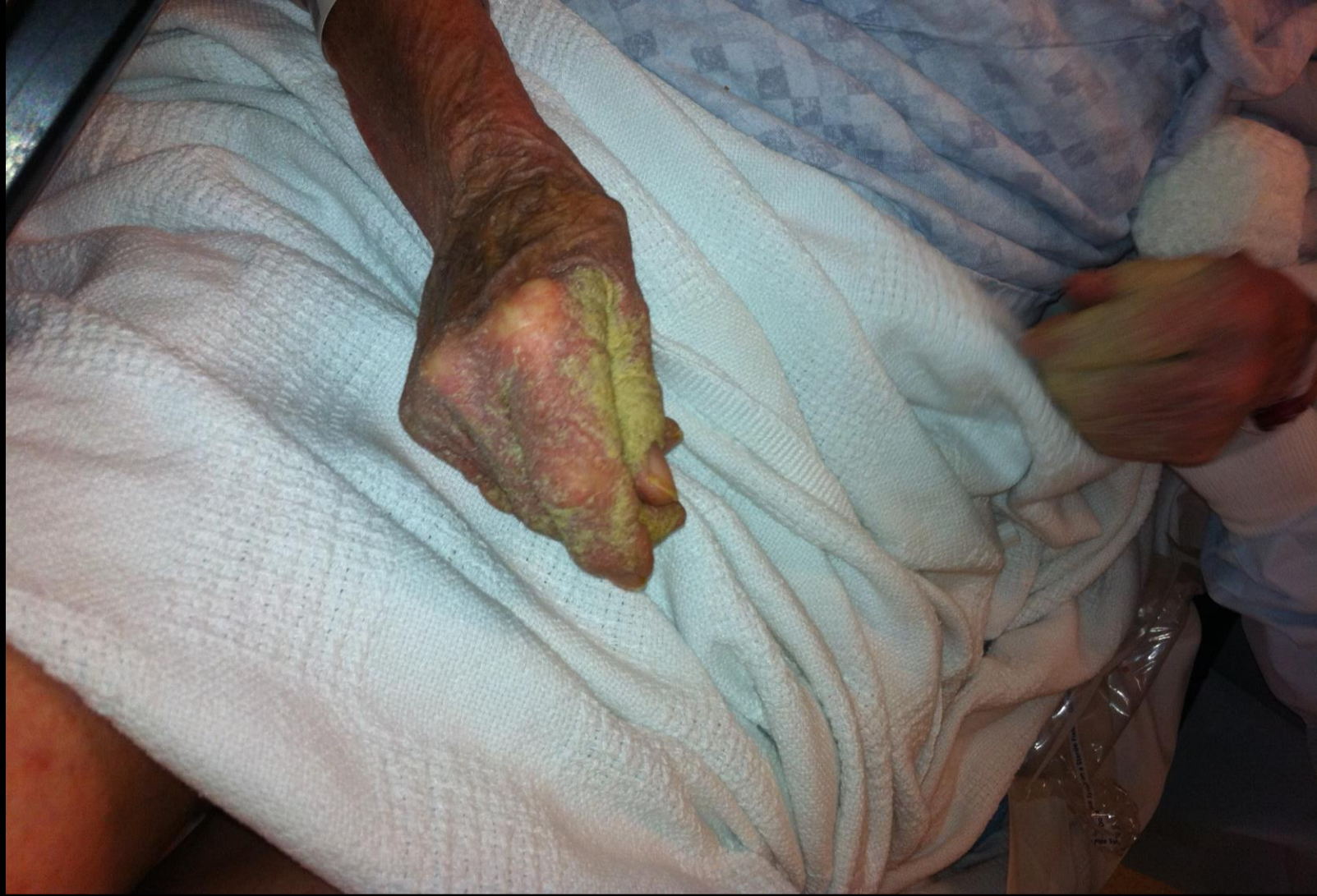

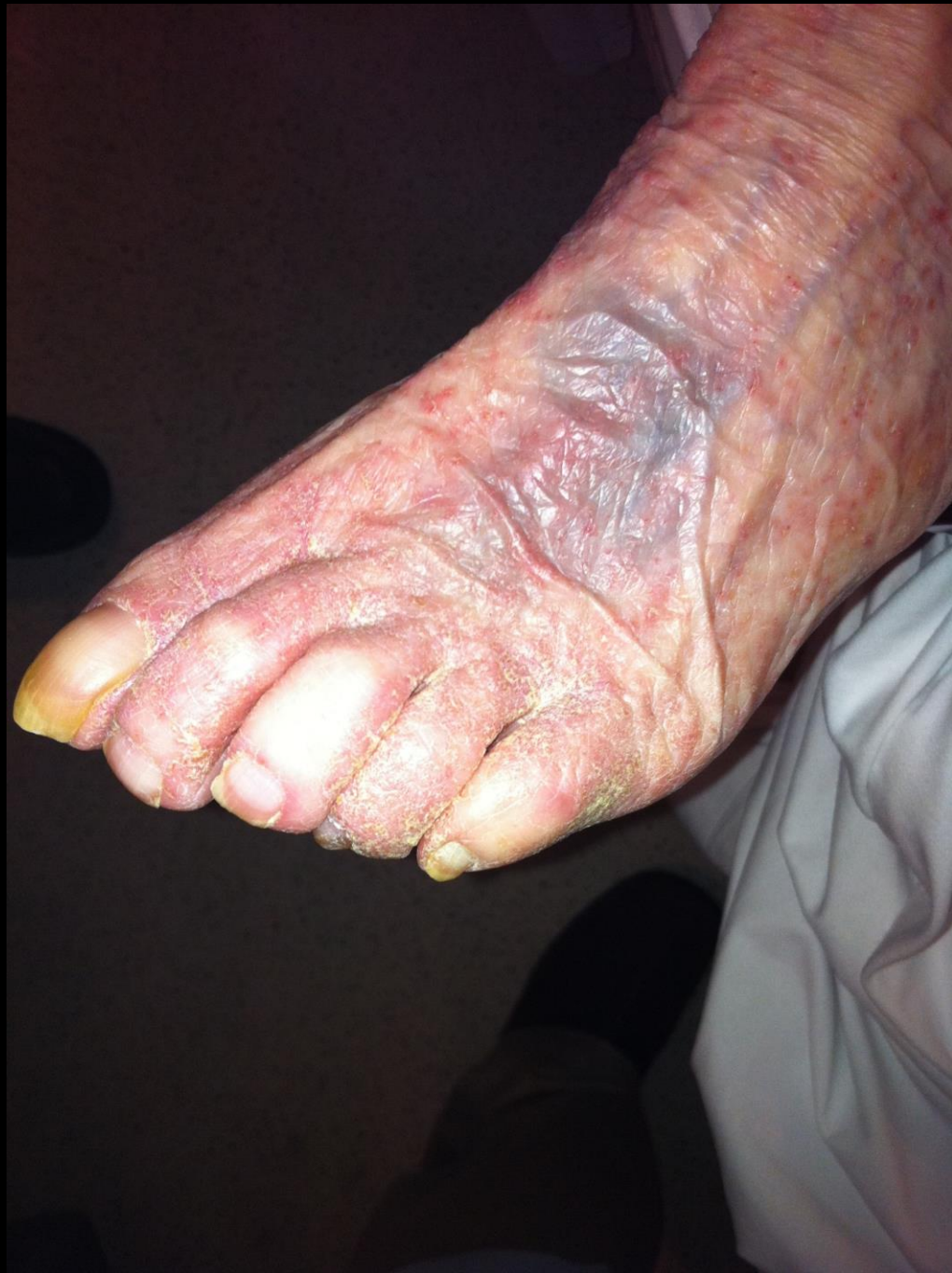1. Infestations



Crusted scabies in an immuno-compromised patient

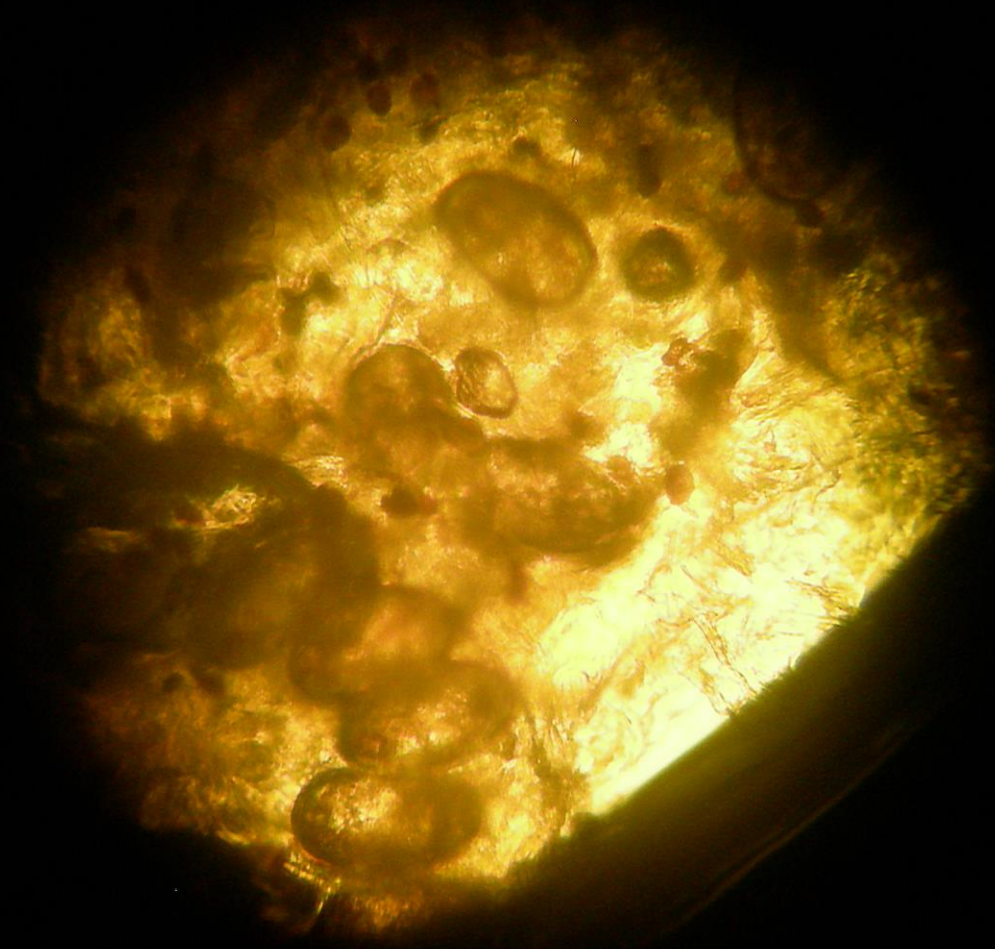




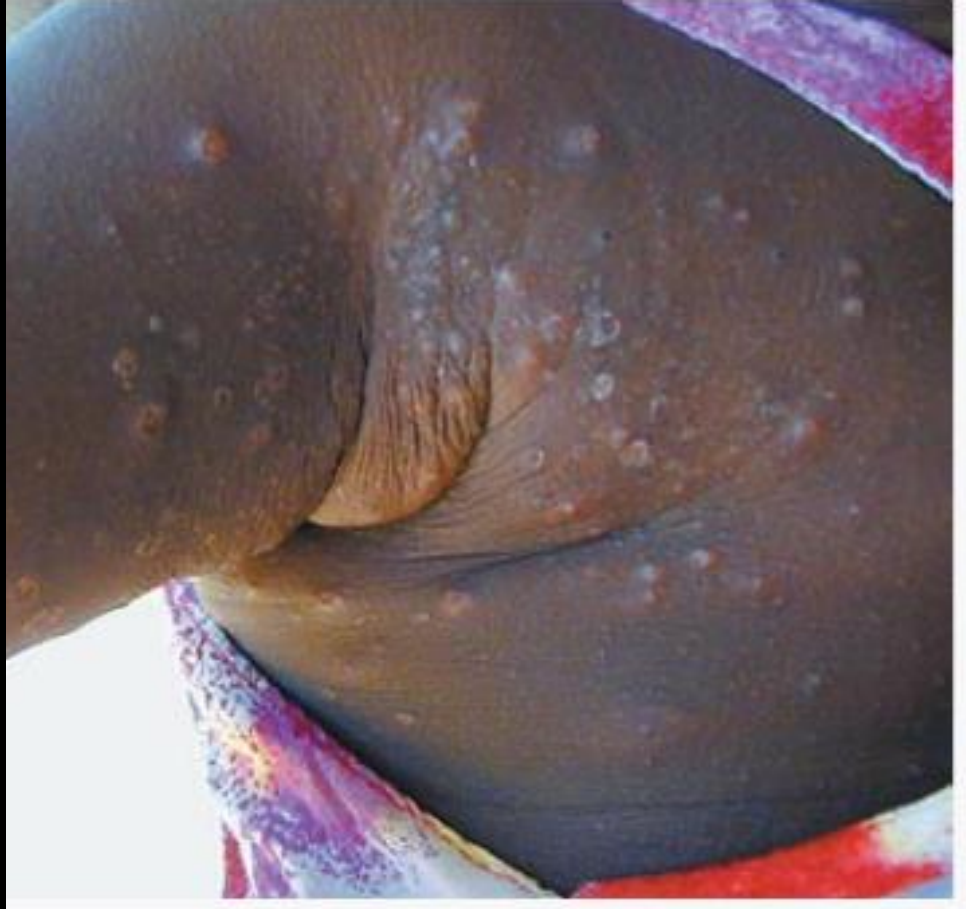

Scabies mite





Morphology



Curry and McCarthy, NEJM 362;8. February 25, 2010

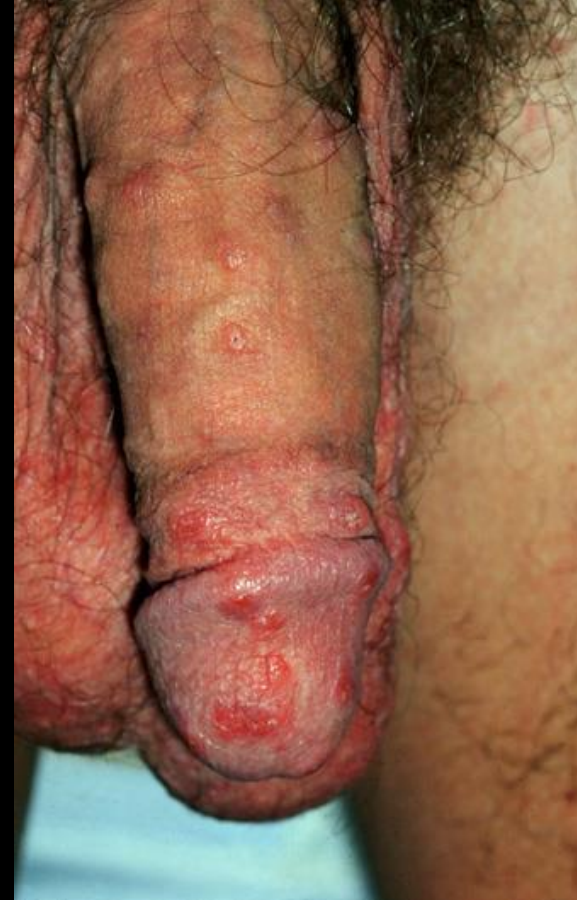

Photo courtesy of William James, MD.
From "Scabies,"
emedicine.medscape.com



Scabies outbreaks in ten care homes for elderly people:
a prospective study of clinical features, epidemiology,
and treatment outcomes



Jackie A Cassell, Jo Middleton, Ananth Nalabanda, Stefania Lanza, Michael G Head, Jennifer Bostock, Kirsty Hewitt, Christopher Iain Jones, Charles Darley, Simran Karir, Stephen L Walker

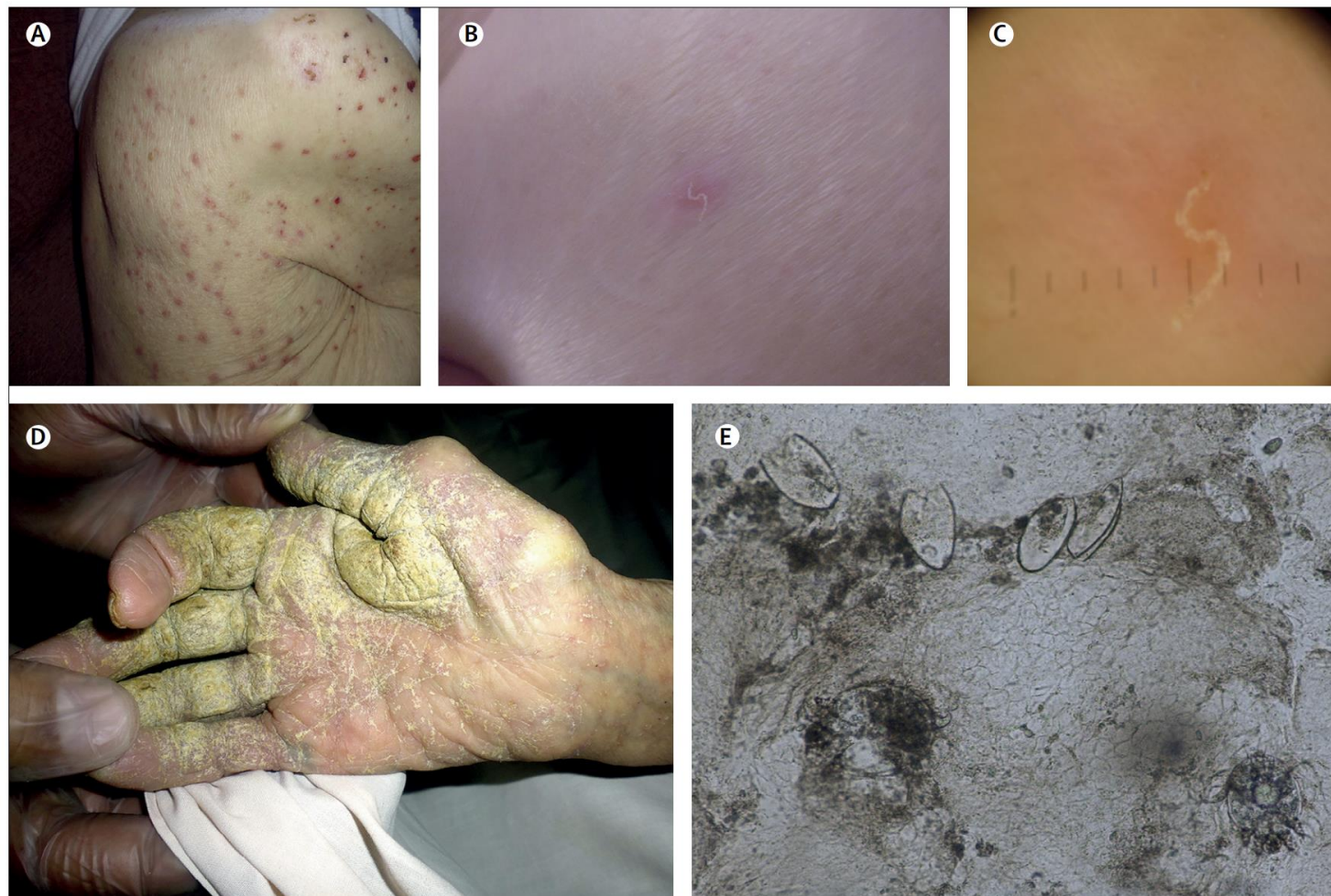


Figure 1: Scabies signs: papules (A), burrows (B), burrows under dermatoscopy (C), hyperkeratotic skin crusts (D), and *Sarcoptes scabiei* mites and eggs under $\times 10$ microscopy (E)

CLINICAL PRACTICE

Scabies

Olivier Chosidow, M.D., Ph.D.

Scabies treatment

Table 2. Current Treatments for Scabies.*

Generic Drug Name	FDA Approval for Treatment of Scabies	Dose	FDA Pregnancy Category†	Major Side Effects or Contraindications	Comments
Topical treatment‡					
Permethrin§	Yes	5% Cream, rinsed off after 8–14 hr	B	Itching and stinging on application; may be used in infants and nursing mothers	First-line topical therapy in the United States; a second administration 1 wk after the first often routinely prescribed; treatment failure potentially attributable to incorrect application or a failure to treat all contacts
Oral treatment					
Ivermectin**	No	Single dose of 200 µg/kg of body weight (commercially available as 3-mg tablets); 2nd dose recommended 14 days later	C	Excess risk of death for elderly patients not confirmed	Approved in France, the Netherlands, and Mexico; cost may vary widely and could be a limitation for use; post-marketing surveillance of various age groups (e.g., children and the elderly) and large populations needed

2. Worms



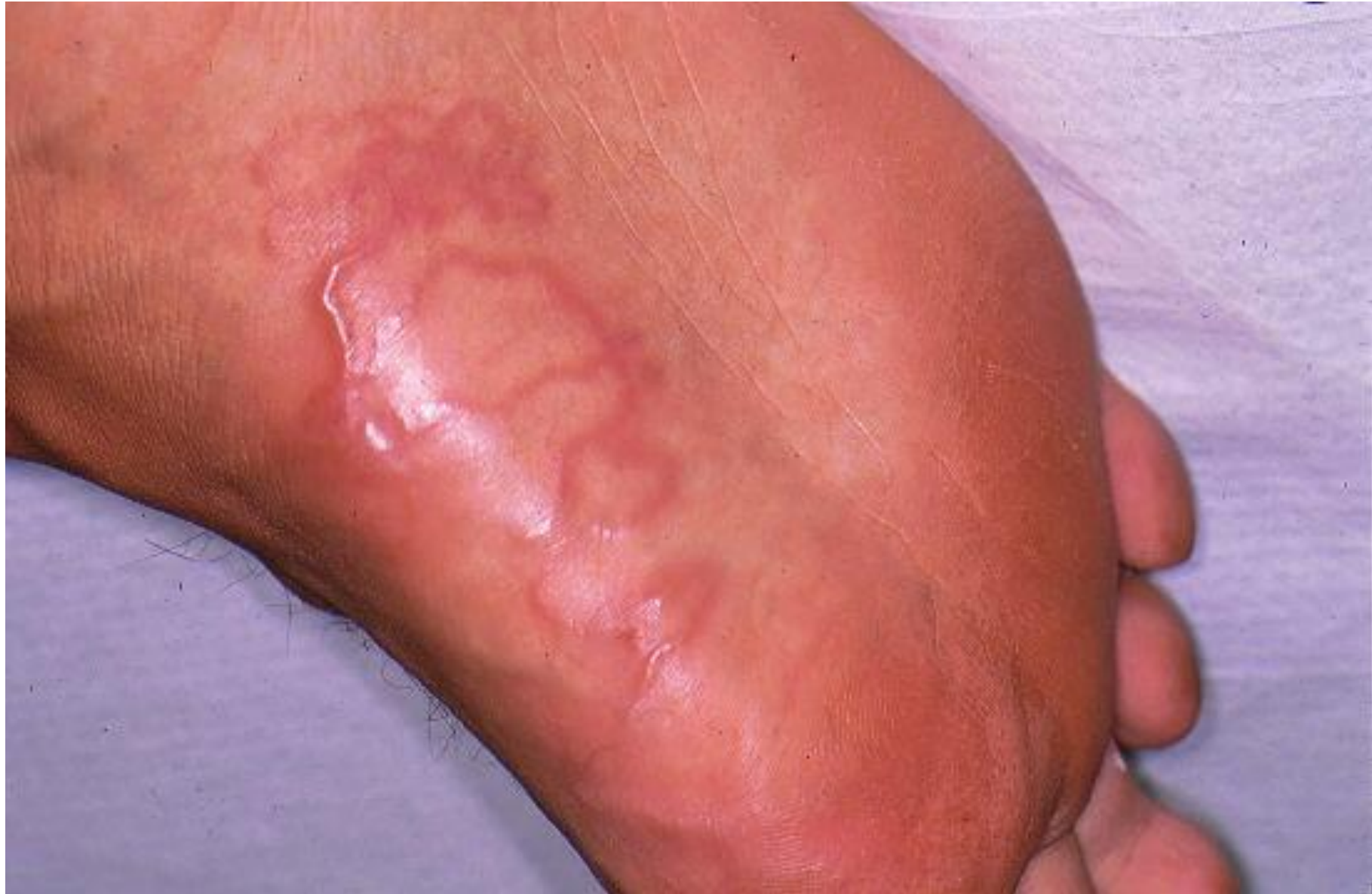


Image courtesy of infectionnet.org

Cutaneous larva migrans

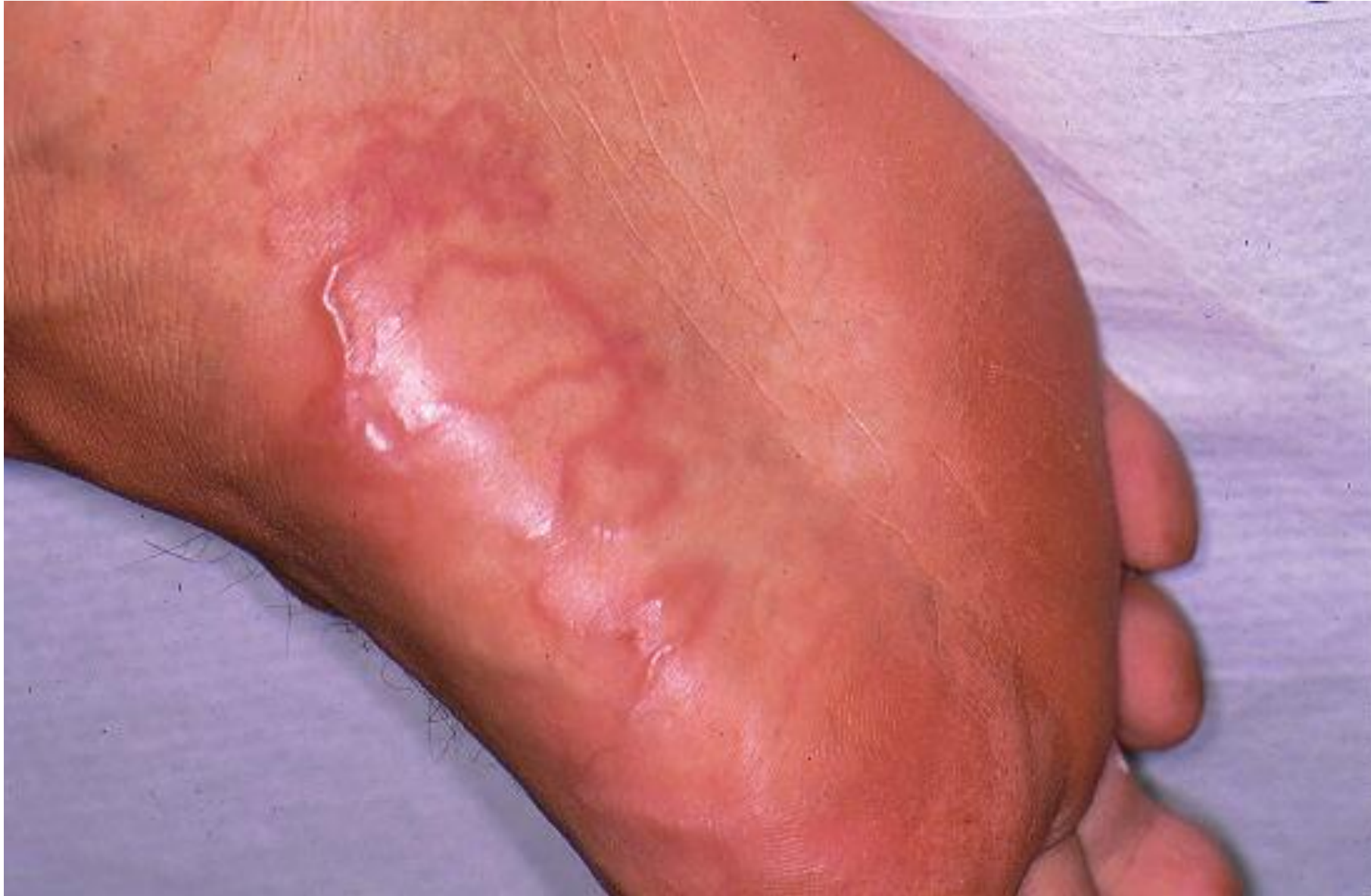
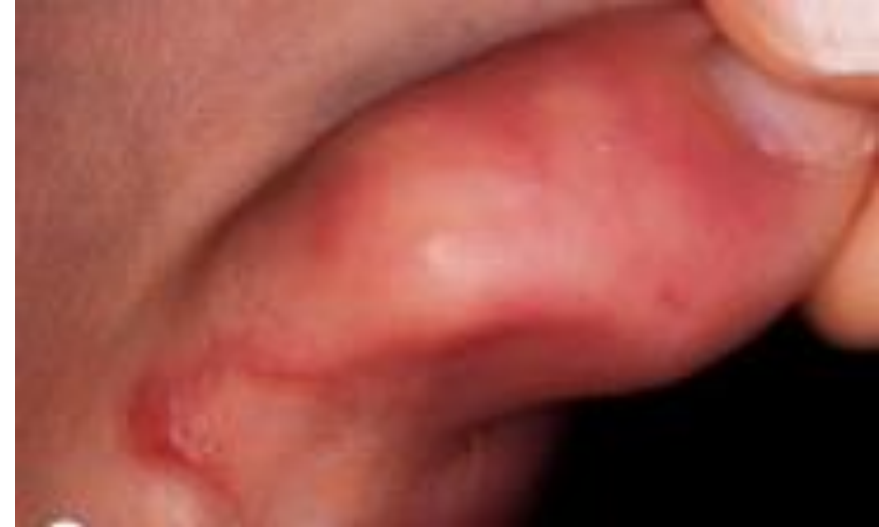
Image courtesy of infectionnet.org

Pt c/o lesions that advance 2 cm per day. Which is true:

- A) Most likely *S. stercoralis*
- B) Iron deficiency anemia will be seen in 4 mo
- C) Ivermectin is an effective treatment
- D) Treatment of choice is cryotherapy at the advancing edge



Bolognia et al. Dermatology. 3rd Edition

Cutaneous Larva Migrans

Pt c/o lesions that advance 2 cm per day. Which is true:

- A) Most likely *S. stercoralis*
- B) Iron deficiency anemia will be seen in 4 mo
- C) Ivermectin is an effective treatment**
- D) Treatment of choice is cryotherapy at the advancing edge



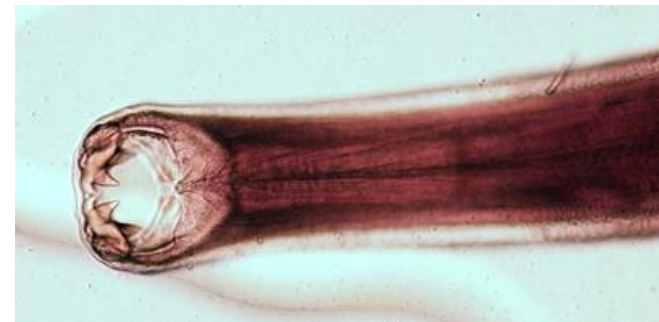Bolognia et al. Dermatology. 3rd Edition

Cutaneous Larva Migrans

- Accidental penetration by animal hookworms
- **Ancylostoma braziliense** (hookworm of domestic dogs and cats) most common
- Edematous, serpiginous tract that advances daily
- Self limited (ITCHY!), but can treat w/ Ivermectin or Albendazole

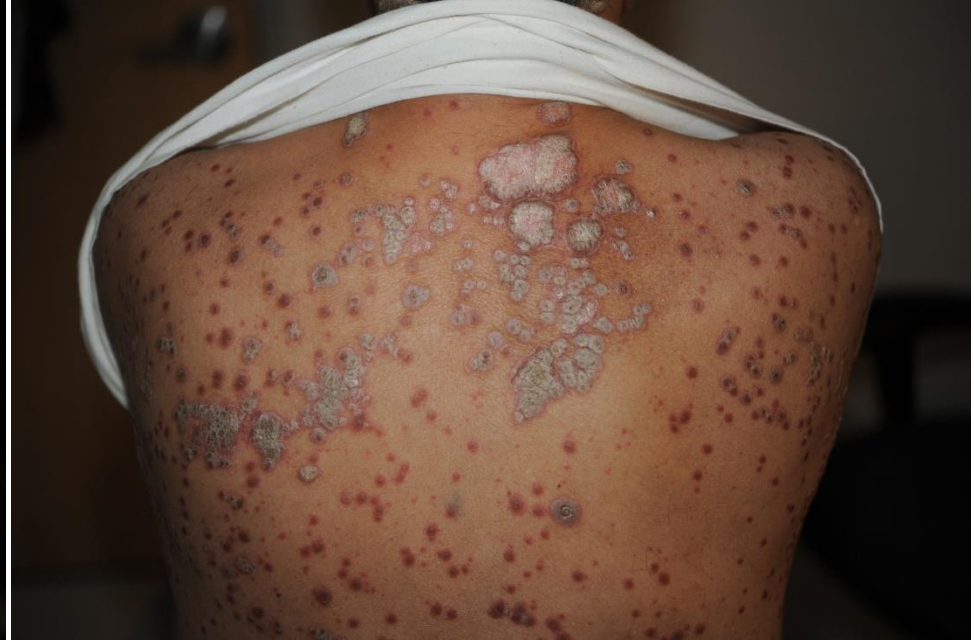
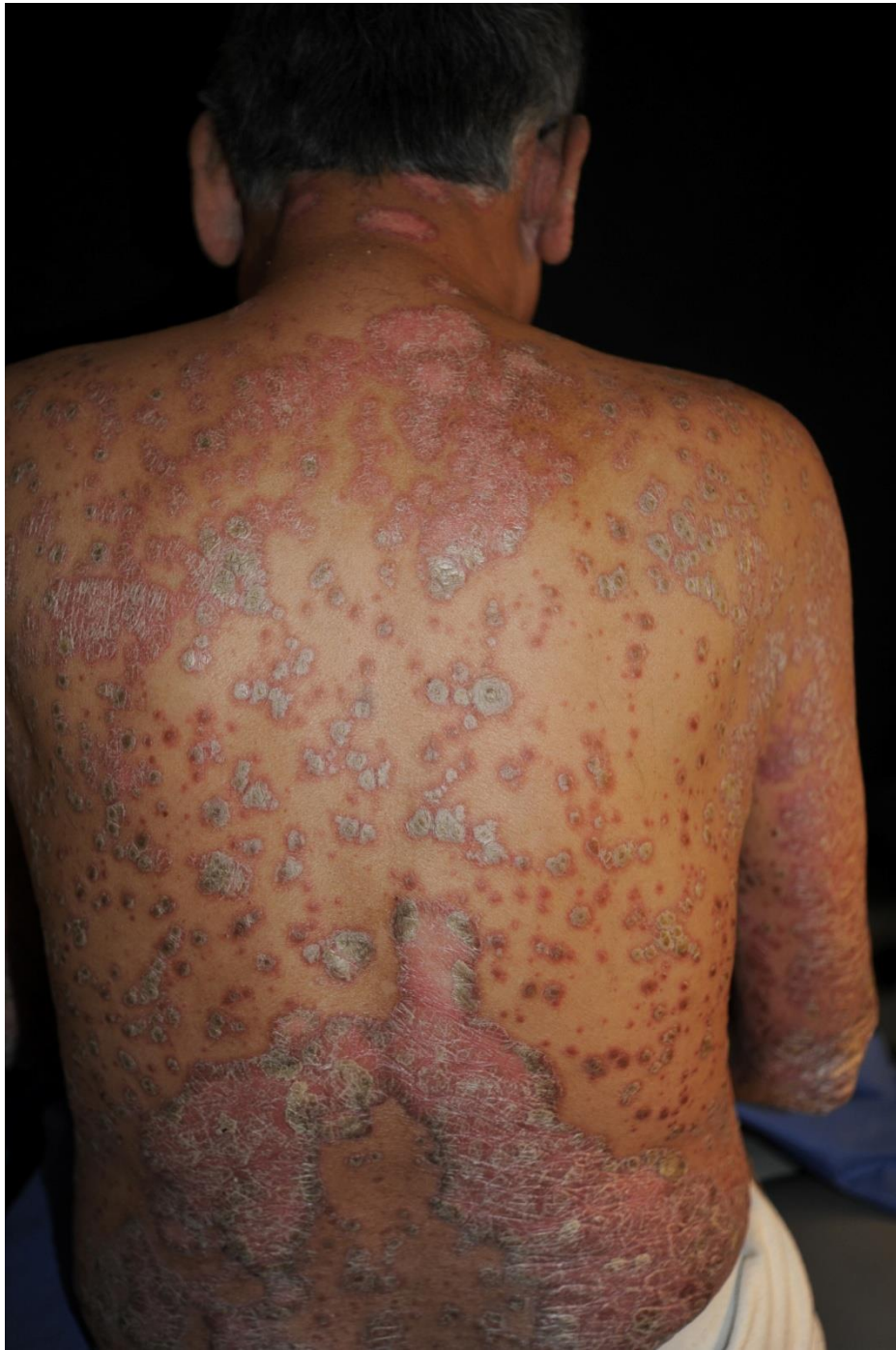
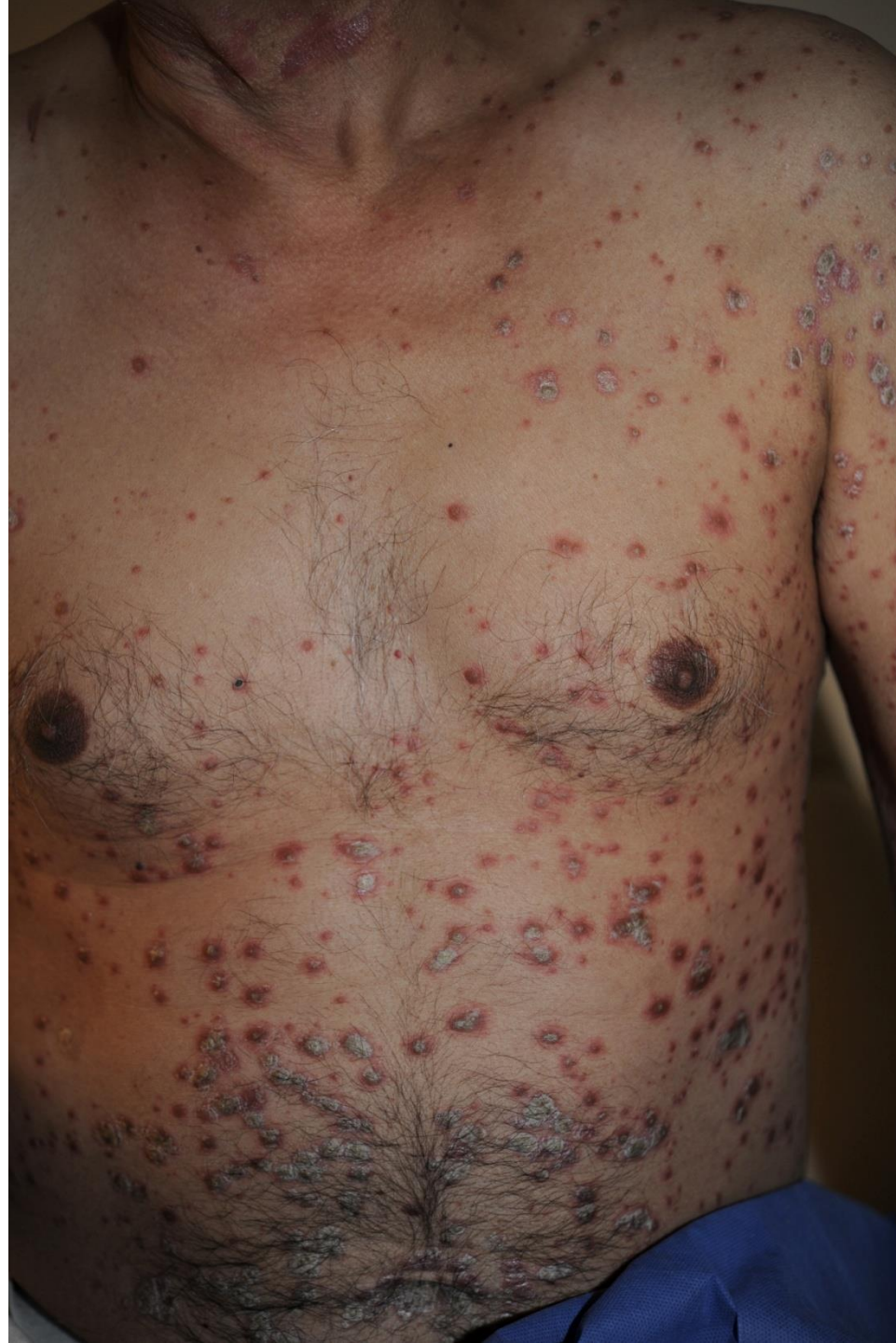Bolognia et al. Dermatology. 3rd Edition

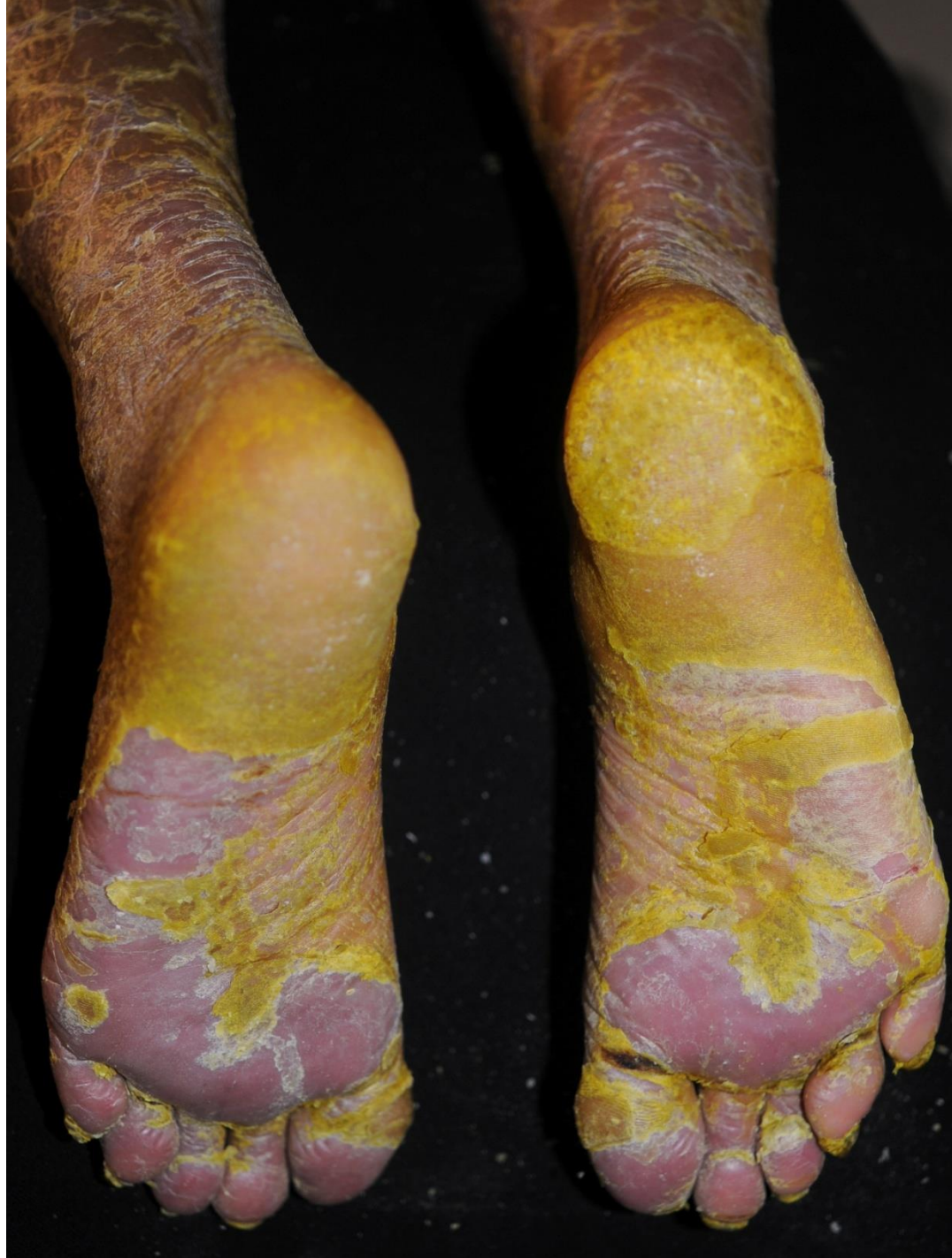
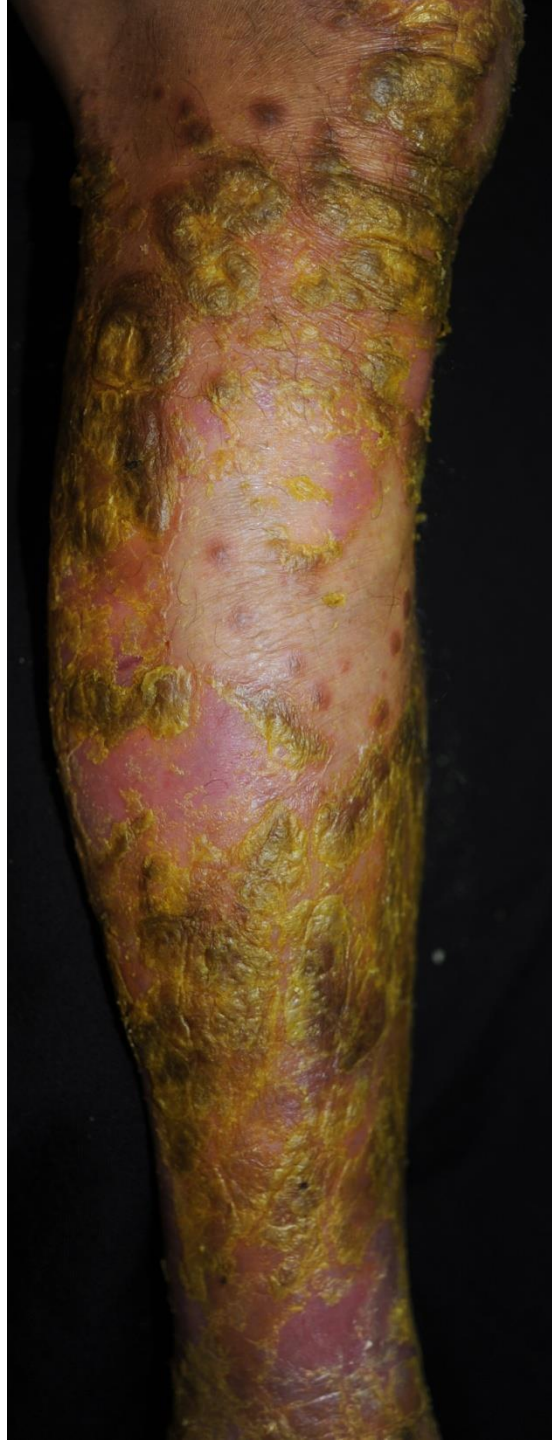
World Atlas of Medical Parasitology atlas.or.kr

A full body rash in the returning traveler...







?



- Yellow?
 - Tumeric
- Thick micaceous plaques?
 - Psoriasis
- Odd distribution?
 - Keobner
- What was the original rash?

Psoriasis koebnerized to Chikungunya

- 63 yo M, presented to MGH Derm clinic
- Viral illness began a few weeks prior while travelling in India (Calcutta)
- Significant lower extremity edema, viral exanthem, joint pain
- Diagnosed w/ Chikungunya in India, convalescent titres here positive
- Subsequently developed psoriasis plaques at sites of viral exanthem
- Tx: Methotrexate 10mg weekly

Travel

SUBSCRIBE | LOG IN

A Mosquito-Borne Virus Sweeps the Caribbean



Fumigating against mosquitoes in Santo Domingo in the Dominican Republic.

RICARDO ROJAS / REUTERS

NOVEMBER 5, 2014

Update

It started with a nagging pain in his wrists

shots

your health treatments & tests he

public health

Chikun-What? A New Mosquito-Borne Virus Lands In The U.S.

JULY 03, 2014 3:08 AM ET

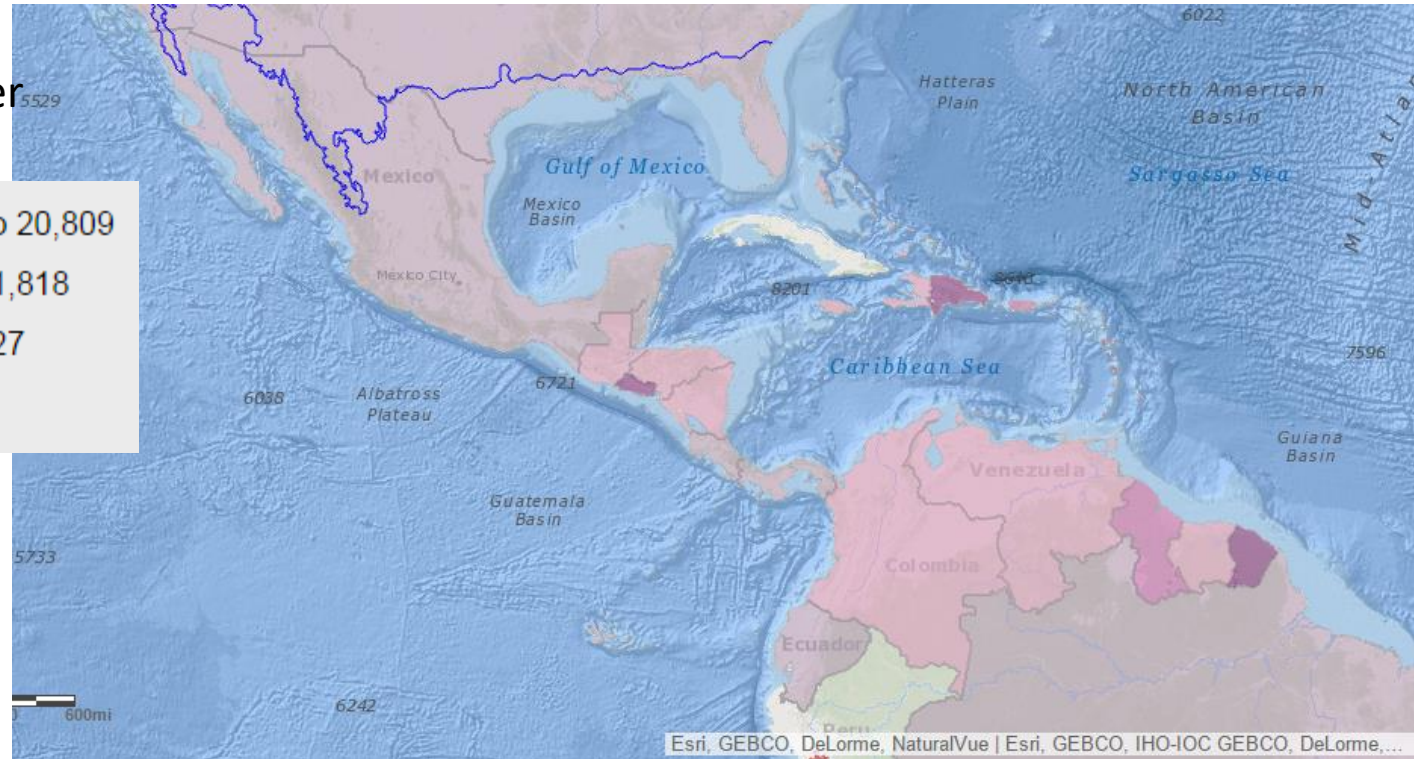
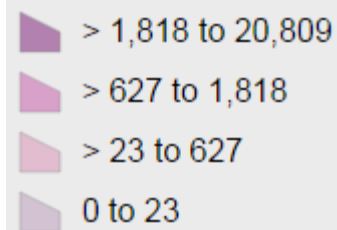
MICHAEELEN DOUCLEFF



Listen to the Story

Chikun-What?

Incidence per
100,000:



- Viral disease (alphavirus)
- Transmitted by mosquitos
 - *Aedes aegypti* and *Aedes albopictus*
- High fever, joint pain, muscle pain, headache

Dermatologic manifestations of Chikungunya

Table 1. Frequency of acute symptoms of CHIKV Infection.^a

Symptom or sign	Frequency range (% of symptomatic patients)
Fever	76–100
Polyarthralgias	71–100
Headache	17–74
Myalgias	46–72
Back pain	34–50
Nausea	50–69
Vomiting	4–59
Rash	28–77
Polyarthritis	12–32
Conjunctivitis	3–56

- Rash 2-5 days after onset fever
- Viral rash
- Trunk and extremities, can include face, palms, soles
- Erythroderma
- Children: vesicobullous

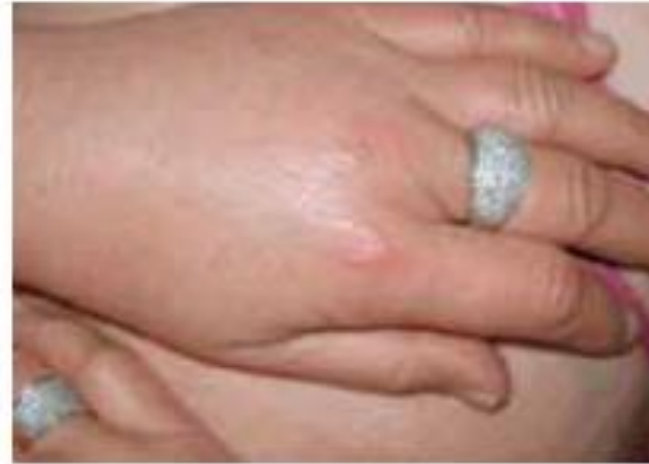^aTable compiled from a number of different studies.^{8, 9, 12-17}

Chikungunya - acute

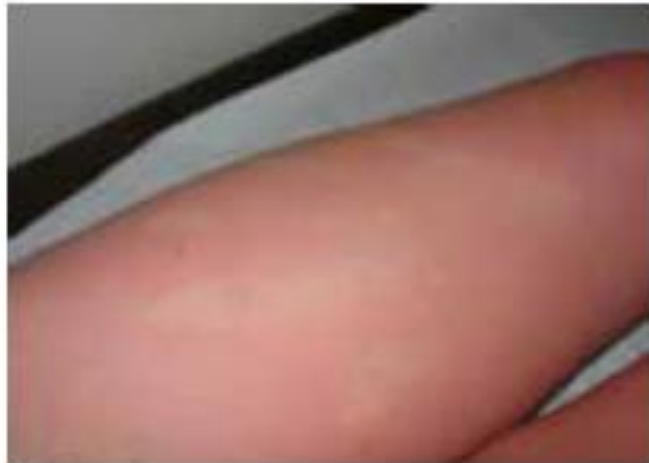Clinical presentation. Acute disease.



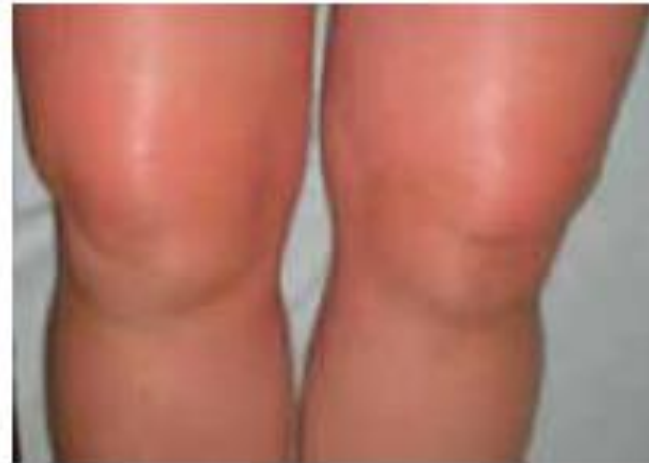A. Edematous rash of the face



B. Edematous polyarthritis of the hands

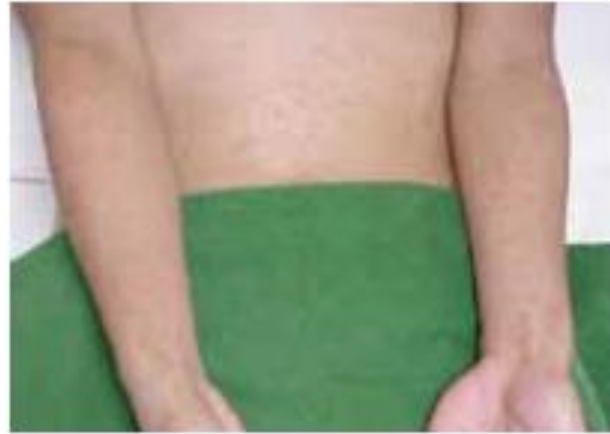

C. Erythema that blanches with pressure

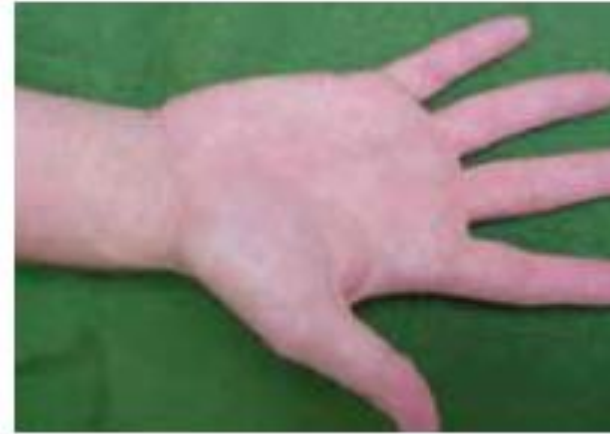

D. Periarticular swelling and joint effusion in knees

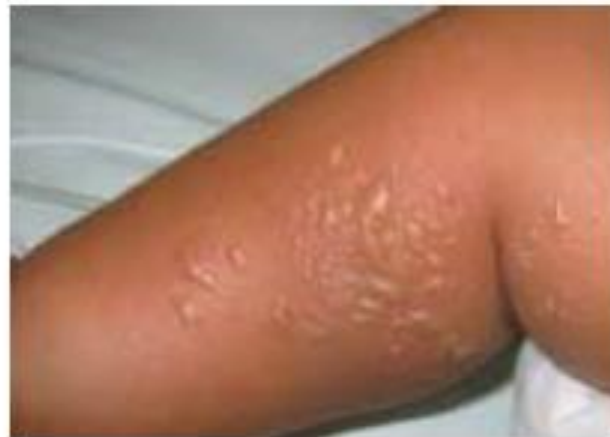Chikungunya - acute



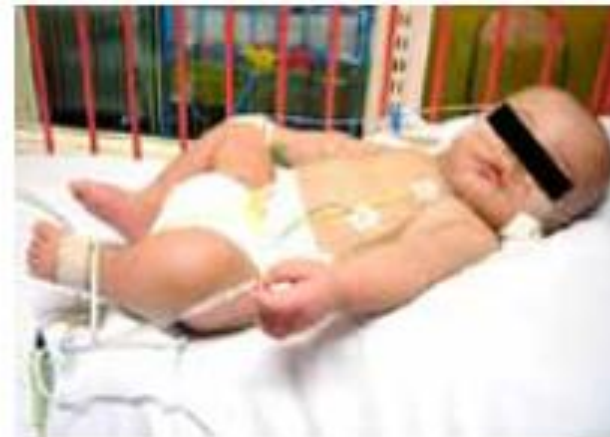E. Maculopapular rash in trunk and extremities



F. Maculopapular rash in extremities, including palms



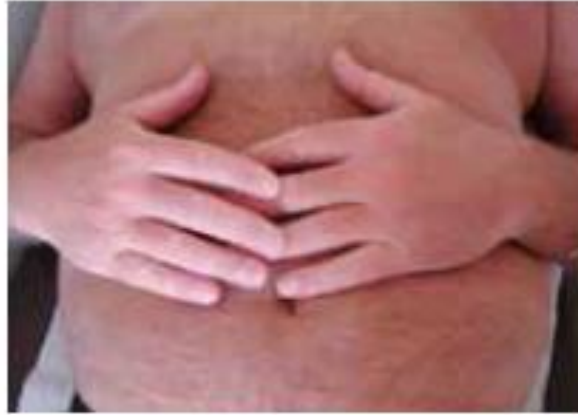G. Bullous lesions in infant leg



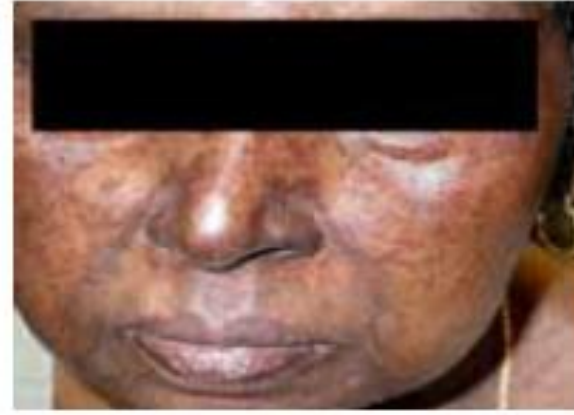H. Infant with maculo-papular rash, petechial spots and erythema of upper and lower limbs associated with edema of the extremities

Chikungunya – subacute, chronic

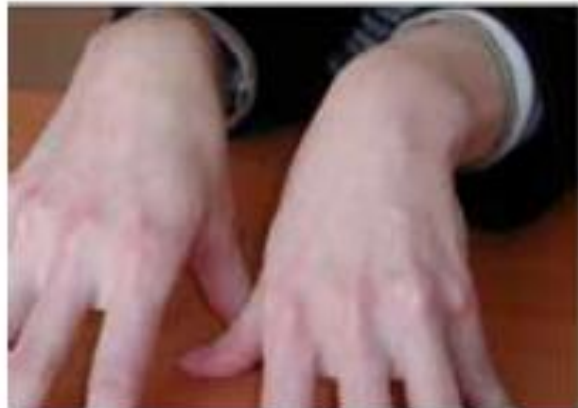Clinical presentation. Subacute and chronic disease.



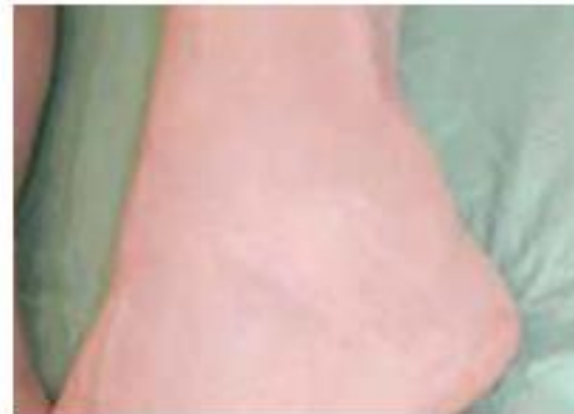I. End of the acute stage. Swollen hands and fine desquamation



J. Hyperpigmentation



K. Tenosynovitis in hands



L. Tenosynovitis in ankle

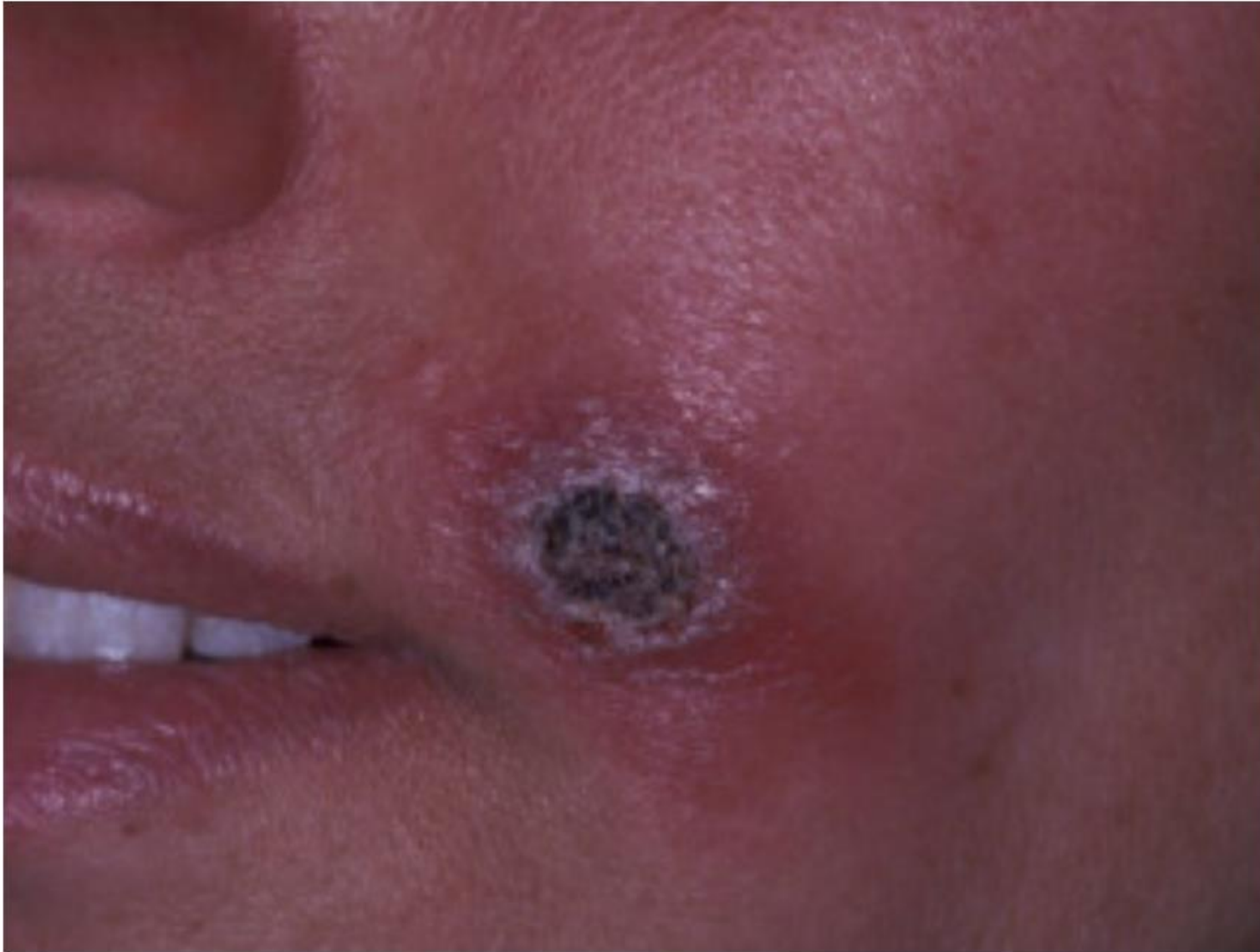Diagnosis of Chikungunya

- Collect two samples: i) acute ii) convalescent (10-14d)
- Three main diagnostic tests:
 - Viral isolation – acute only
 - Reverse transcriptase PCR (RT-PCR)
 - Serologic (antibodies)

Days post illness onset	Virus testing	Antibody testing
Day 1-3	RT-PCR = Positive Isolation = Positive	IgM = Negative PRNT = Negative
Day 4-8	RT-PCR = Positive Isolation = Negative	IgM = Positive PRNT = Negative
>Day 8	RT-PCR = Negative Isolation = Negative	IgM = Positive PRNT = Positive

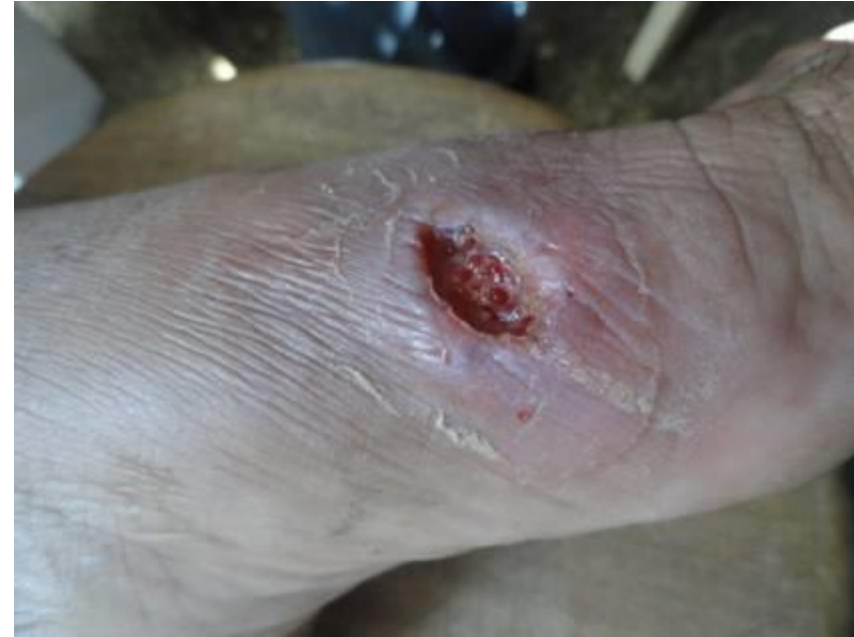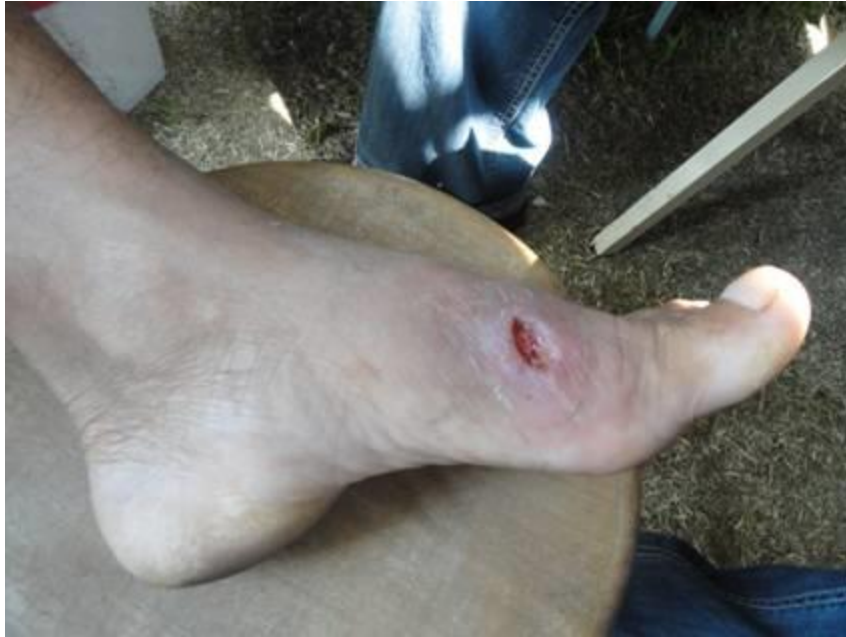3. Last case:

Patient travels to Costa Rica (or Mexico, or Peru...) for a yoga retreat. Comes back with a small non-healing ulcer, that started (in their opinion) like a “pimple”

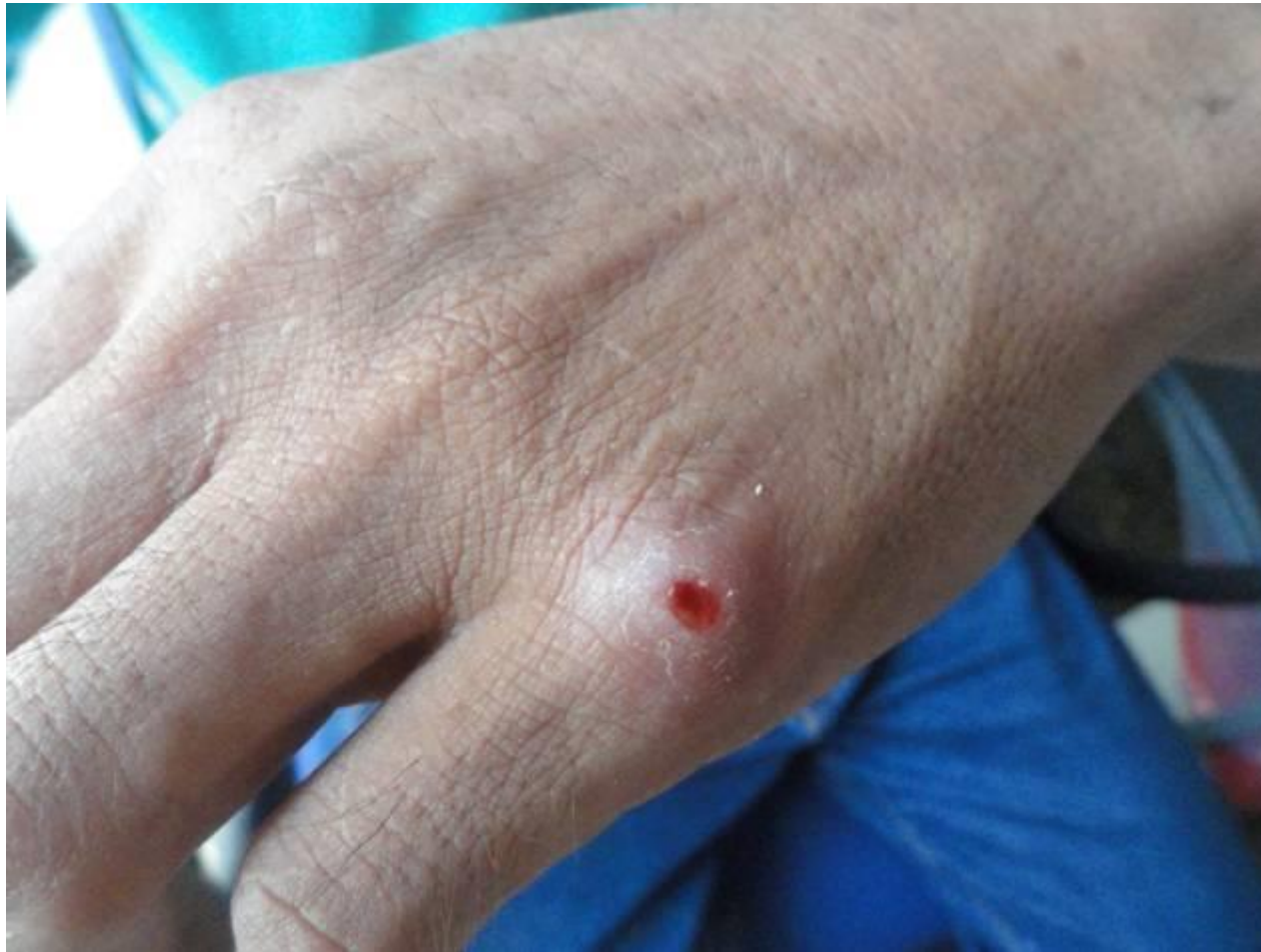

Example image courtesy of dermnet.nz

Small ulcer of the foot

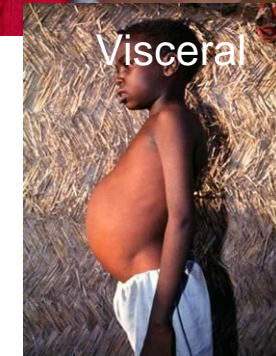
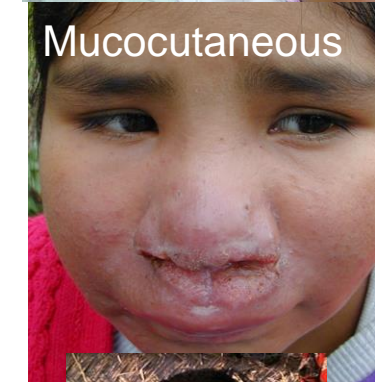
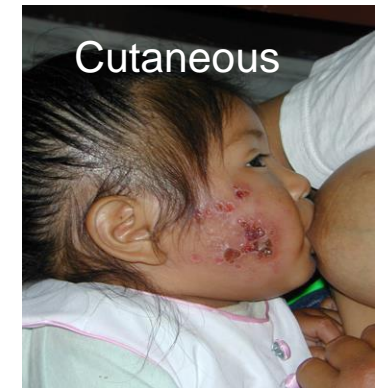Or could be of the hand... or face...

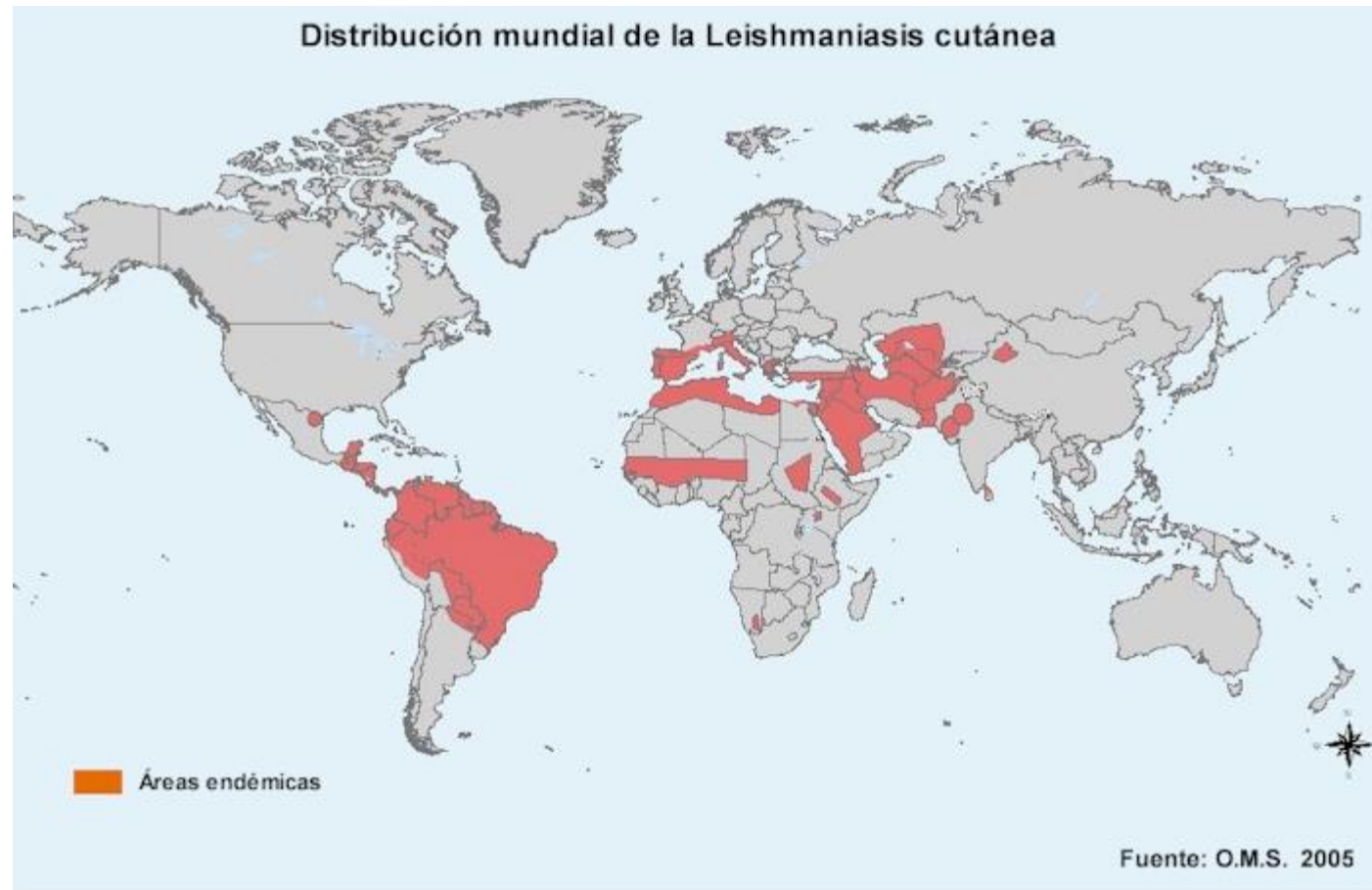

Leishmaniasis Overview

- Vector-borne disease caused by *Leishmania* parasites
- Variety of clinical syndromes:
 - Cutaneous Leishmaniasis
 - Localized
 - Diffuse Cutaneous
 - Disseminated Cutaneous
 - Post-kala-azar dermal
 - Mucocutaneous Leishmaniasis
 - Visceral Leishmaniasis



Cutaneous Leishmaniasis

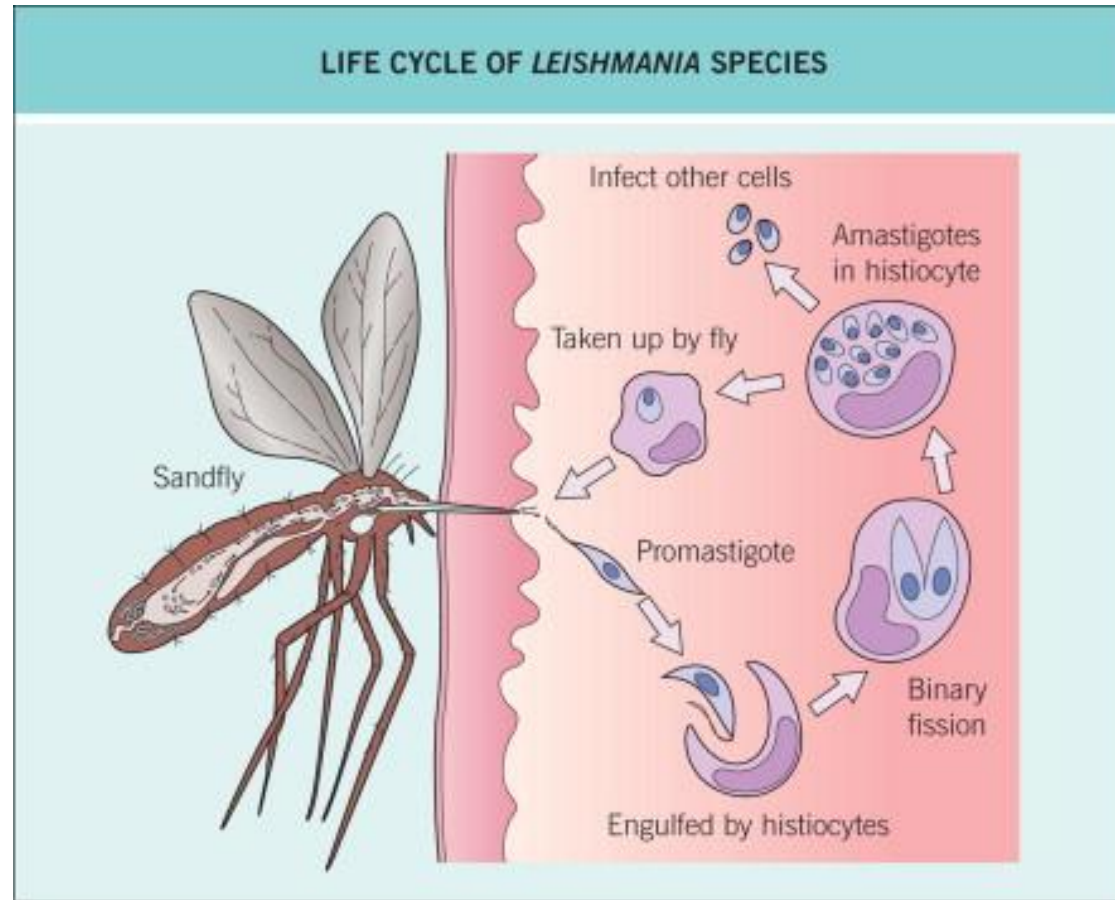


22 New World Countries

66 Old World Countries

Source: World Health Organization, Essential Maps

Leishmaniasis



- Only female sandflies suck blood: sandfly vomits on human skin, then bites
- Eggs are planted in dark humid places, like under stones and rotten leaves
- Humans are incidental host; rodents, dogs, and bats are reservoir

Cutaneous Leishmaniasis

- *Leishmania peruviana*
 - High Andean valleys: 800-3000 meters
 - Vector: *Lutzomyia* sand fly (*peruensis*, *ayacuchensis*, *verrucarum*)
 - Hosts: wild rodents, domestic dog
- Other New World cutaneous: *L. mexicana*, *L. braziliensis*, *L. panamensis*, *L. guyanensis*, *L. infantum*

Parasites

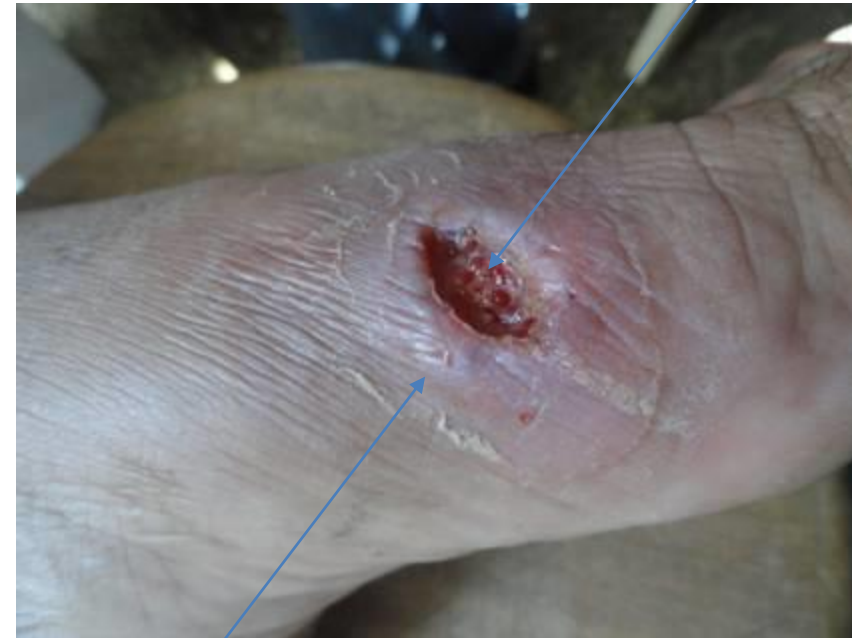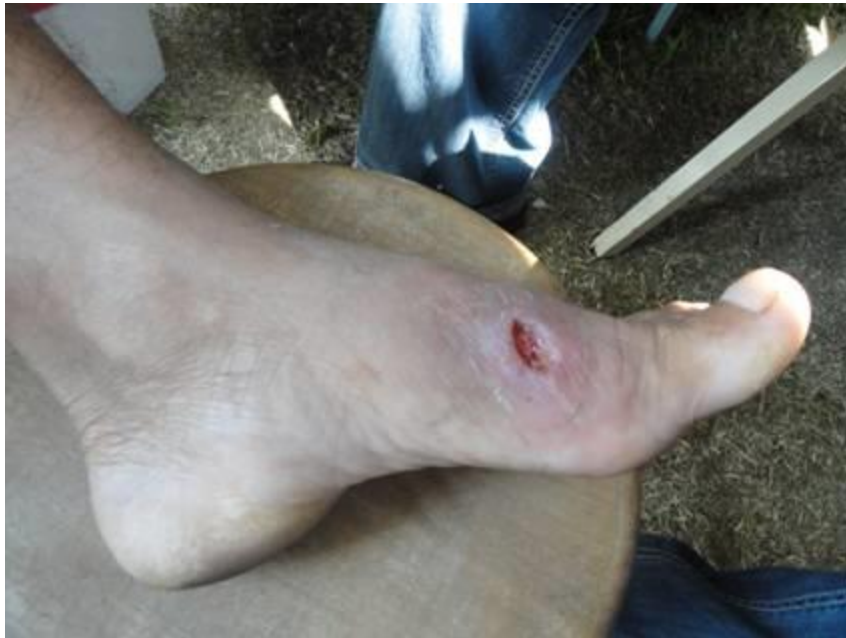Which vector(s) transmit(s) leishmaniasis?

Phlebotomus (Old World)

B. Lutzomyia (New World)



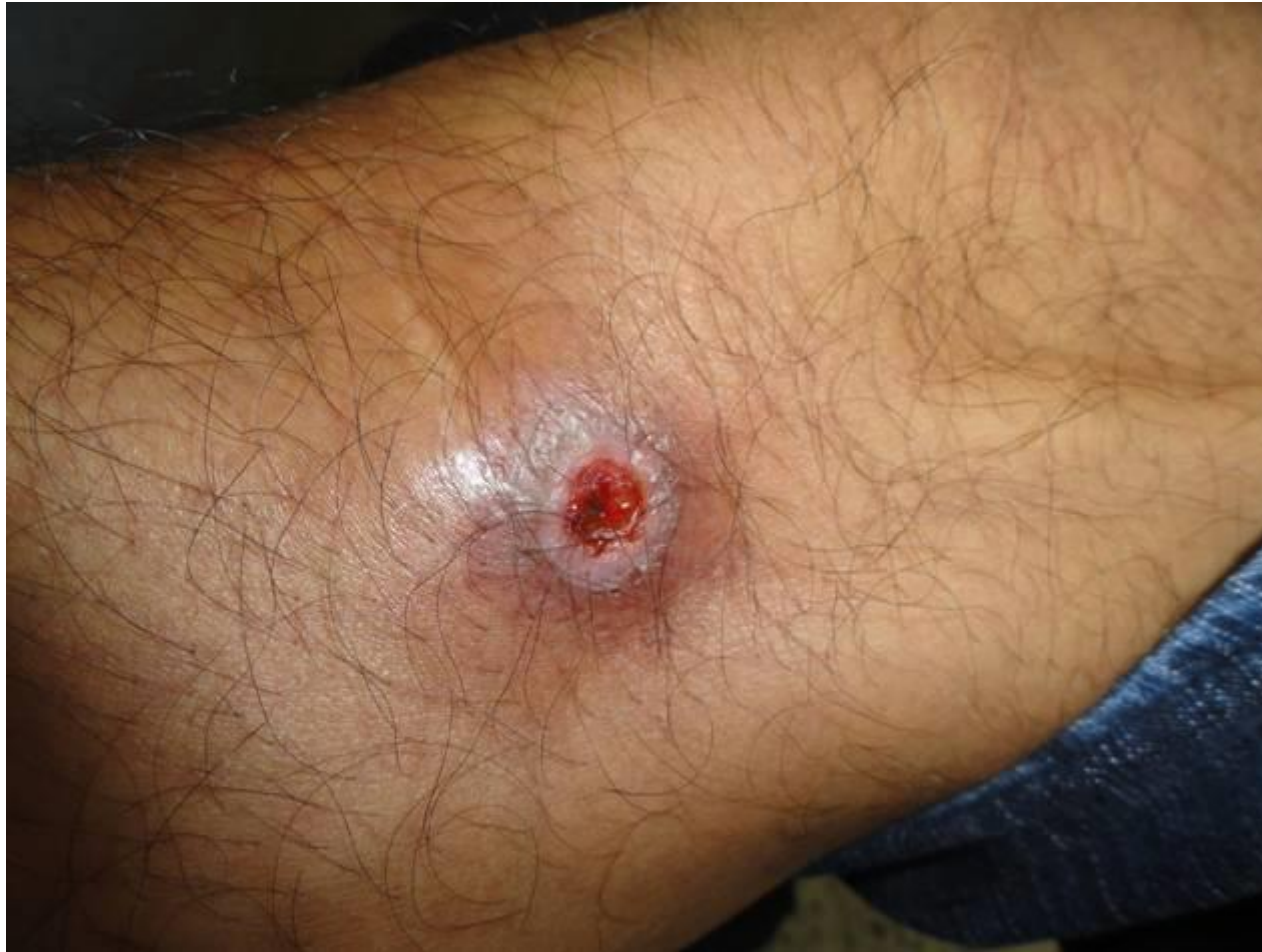Typical ulcers - foot



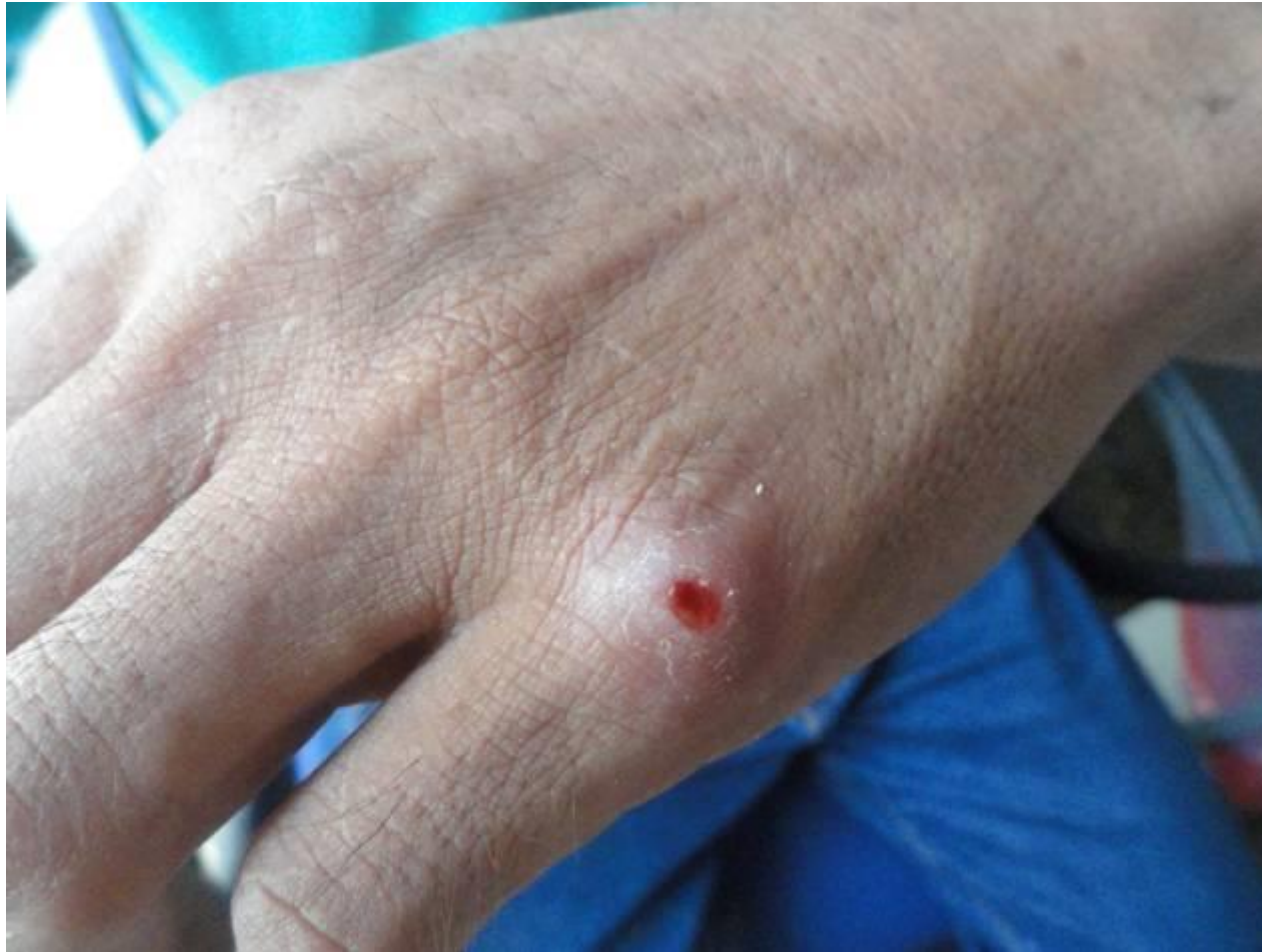Background
granulation
tissue

Defined,
elevated, and
indurated
borders

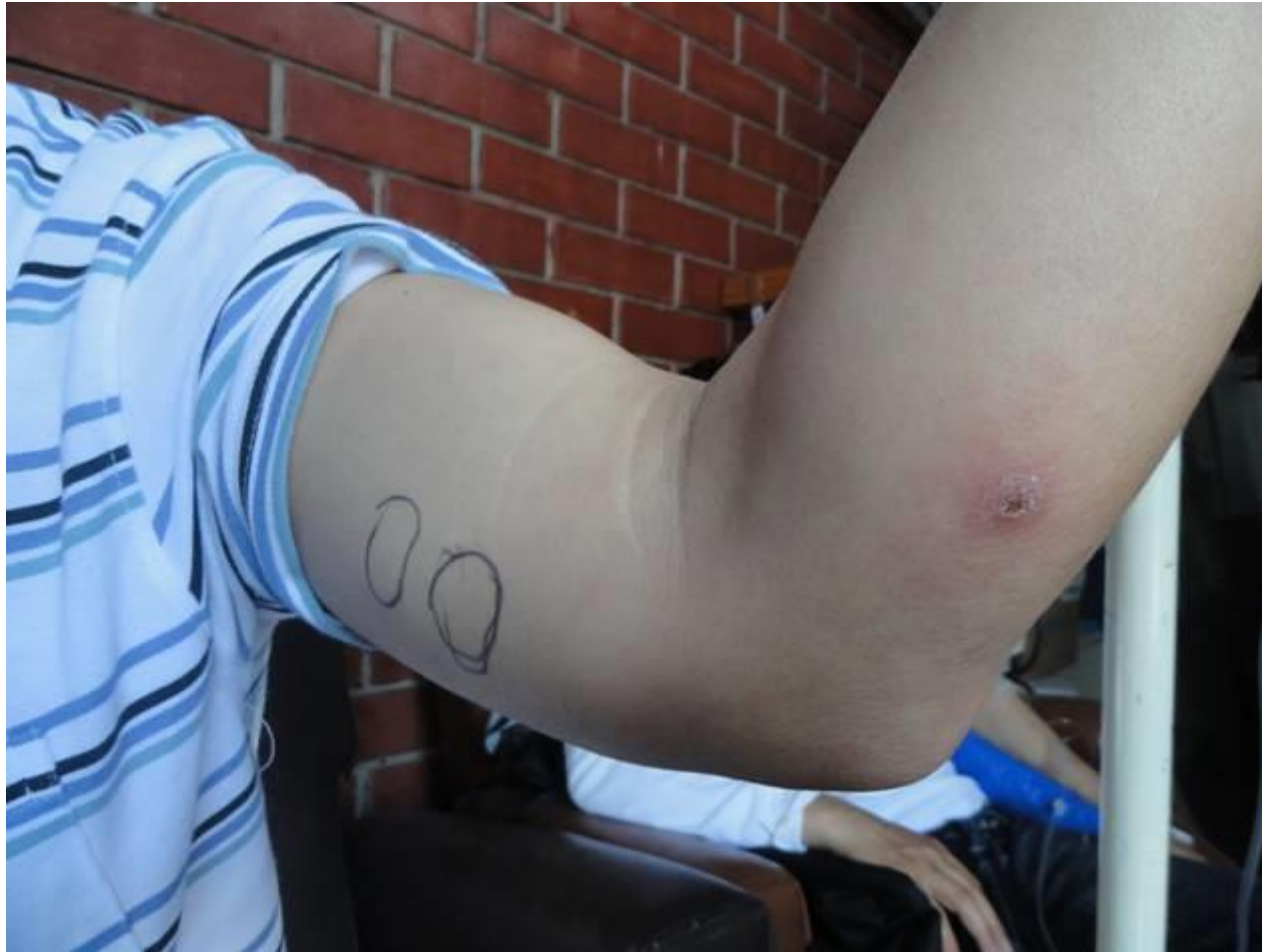Typical ulcers - calf



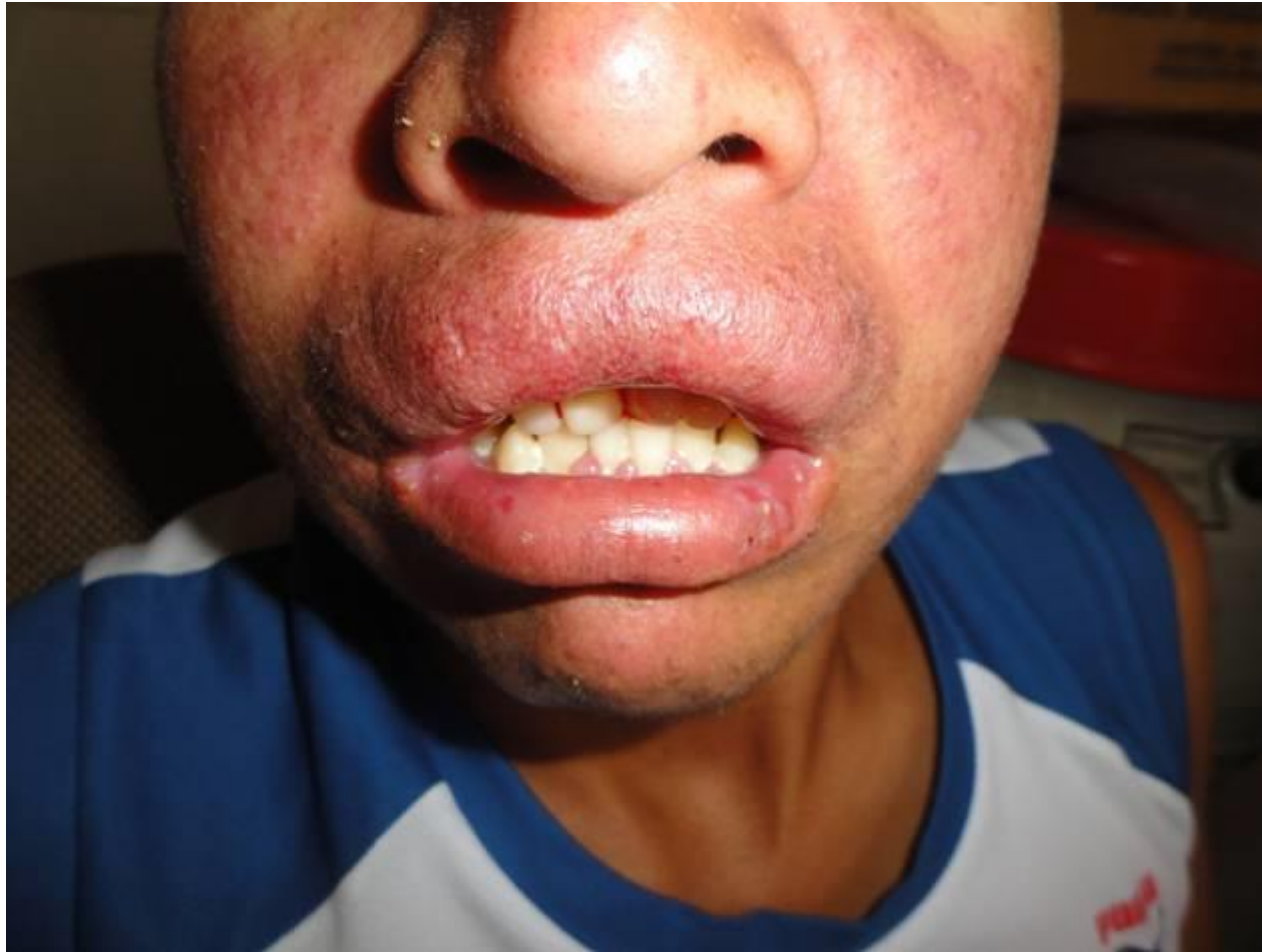Typical ulcers - hand



Subcutaneous lymph nodules



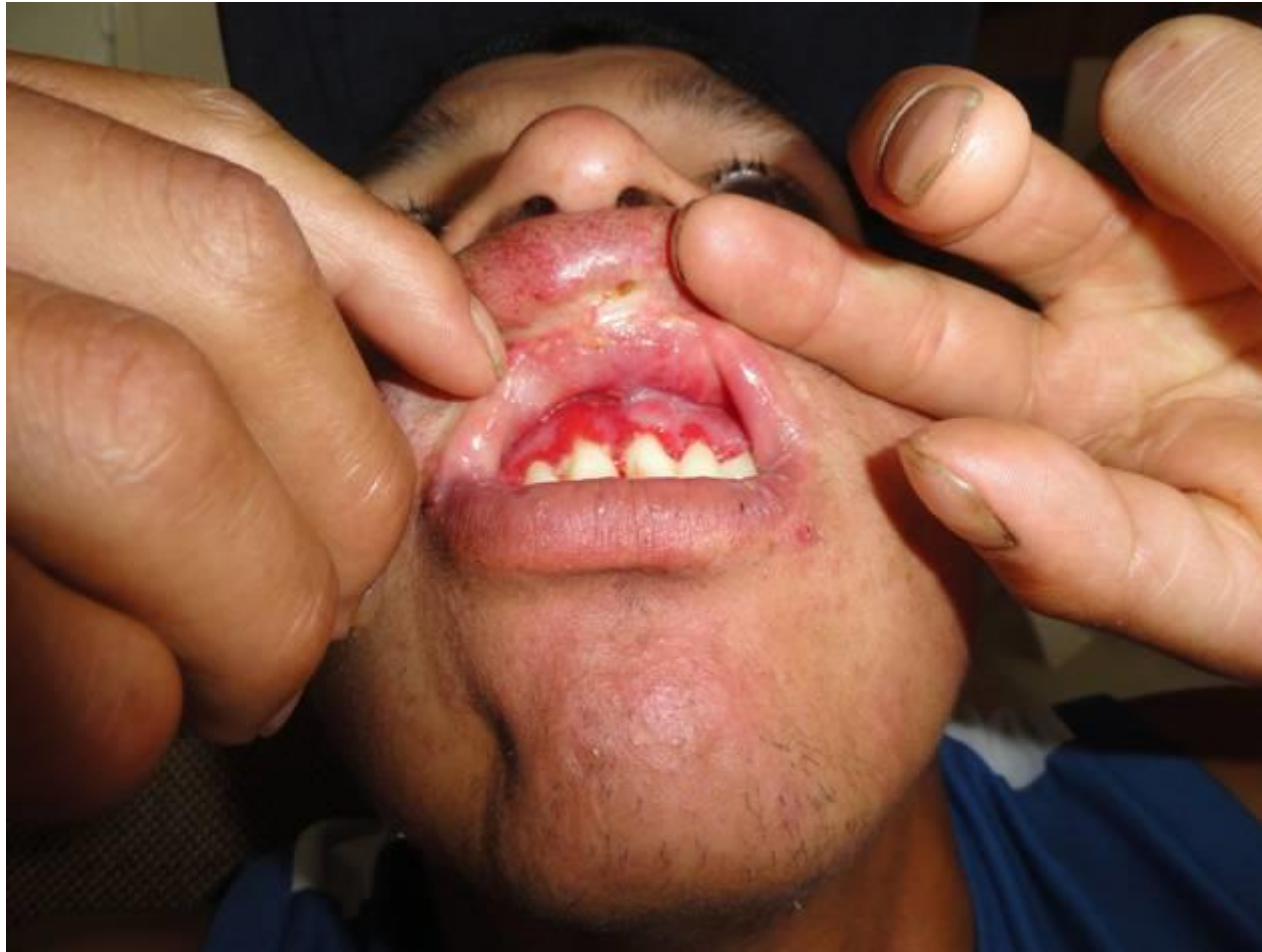What type of Leishmaniasis?



Mucocutaneous Leishmaniasis



Mucocutaneous Leishmaniasis



Mucocutaneous Leishmaniasis

- Secondary lesions
- Delay: months -> 20 years
- Metastasis to the mucosal tissues of the mouth & upper respiratory tract
 - lymphatic or haematogenous dissemination
- Occurs in <5% of *L. braziliensis* and *L. panamensis* infections

Why you need to diagnose and treat mucocutaneous Leishmaniasis

Destruction of nasal septum – can occur years later

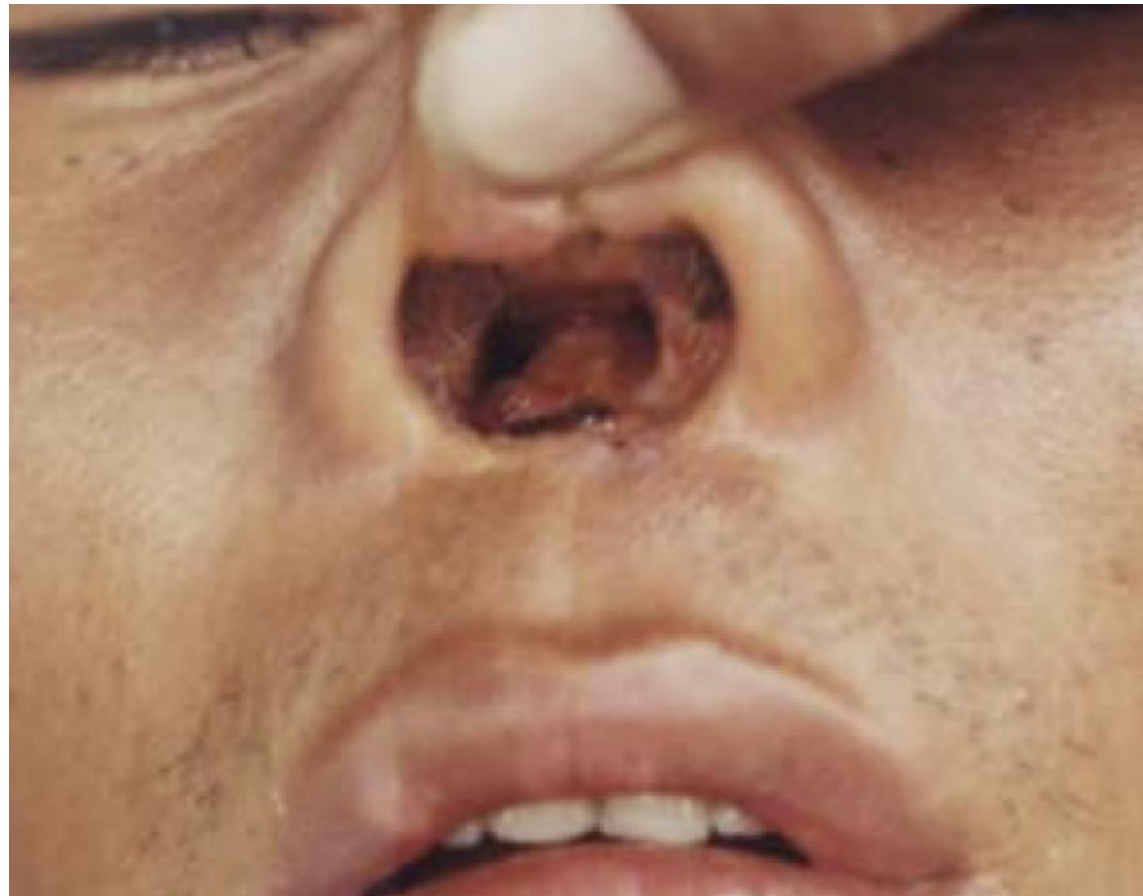


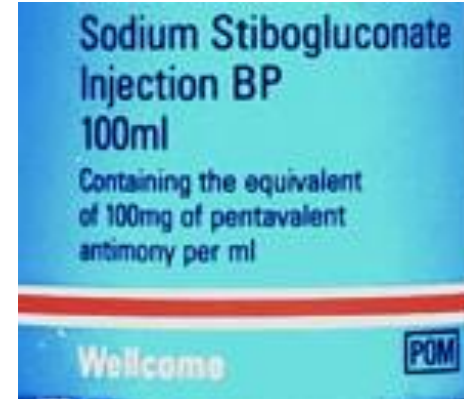Image from Leishmania isoenzyme polymorphisms in Ecuador: Relationships with geographic distribution and clinical presentation. February 2006 BMC Infectious Diseases 6(1):139 DOI: [10.1186/1471-2334-6-139](https://doi.org/10.1186/1471-2334-6-139)

How we diagnose here...

- Send to Dermatology!
- Call Leishmaniasis program at the CDC
- They will send you NNN media for culture
 - Based on culture and PCR, they will speciate for you
 - Treatment based on subtype (Old World cutaneous may not require treatment, New World almost universally requires treatment)
- Other tests: Leish smears, Montenegro (PPD of Leish, rarely used)

Treatment for leishmaniasis

- Always treat VL, MCL, severe CL
- CL:
 - New World – treat
 - Systemics for *L. braziliensis*
 - Old World - Most lesions resolve on their own, monitor for secondary infection
 - Indications for tx: Large, disfiguring, face, near MM, over joints



Treatments for leishmaniasis

- Pentavalent antimony (Na stibogluconate, meglumine antimonate)
 - 90-97% cure but drug resistance on the rise
 - Side effects
- Amphotericin B for resistant MCL and VL
- Pentamidine IM
 - Resistance in India, high relapse rates
- Paromomycin
 - Often used in combo with antimony

We reviewed:

1. Infestations – scabies
2. Worms – cutaneous larva migrans
3. Selected conditions in the returning traveler
 - Viral - Chikungunya
 - Parasitic - Leishmaniasis



Thank you!

With thanks to...

the Gorgas Course, Universidad Peruana Cayetano Heredia

Dr. Richard Johnson, MGH